

# Femoral Head and Neck Osteotomy (FHO) for Treatment of Different Hip Joint Disorders in Dogs

Fathy D. El-Seddawy, Abdelmeged F. El-Mezayen, Mohamed F. Tantawy,  
Mohamad Gomaa\*

Department of Surgery, Anesthesiology and Radiology, Faculty of Veterinary Medicine, Zagazig University, Egypt.

## \*Correspondence

Mohamad Gomaa

Department of Surgery, Anesthesiology and Radiology, Faculty of Veterinary Medicine, Zagazig University, Egypt.

E-mail address: Gomaasurgeon@yahoo.com

## Abstract

In this research, surgical treatment of hip dysplasia, hip luxation, femoral neck fracture, and degenerative hip joint disease were performed using femoral head and neck osteotomy (FHO). Twelve different breeds of male dogs weighing 14-52 kg suffering from different hip joint disorders were admitted to the Vet. Surgery clinic, Faculty of Vet. Med. Zagazig University and from some different private pet animal clinics. The admitted cases were diagnosed by clinical signs (visual pain assessment and lameness scoring), clinical crepitus exam, and plain radiography. The FHO technique applied in the affected cases revealed successful results with the absence of painful lameness noticed after 3 weeks postoperatively but nonpainful lameness was observed then decreased gradually till disappearance when muscles become stronger to compensate for the absence of the head of the femur with minimal complications. FHO is a very good salvage economic satisfactory technique with minimal complications. Using an oscillating saw and sharp osteotome is better than using of Gigli saw.

## KEYWORDS

Coxo-femoral joint, Femoral head and neck osteotomy (FHO), Hip luxation, hip dysplasia.

## INTRODUCTION

The main functions of a dog's hip joint are attaching the rear legs to the rest of the body supporting their weights and important role in locomotion. Hip disorders bring lameness and painful arthritis (Benzioni *et al.*, 2008). These disorders include femoral head and neck fractures, luxation of the hip joint, hip dysplasia, Legg-Calve-Perth's disease (avascular necrosis) and degenerative joint disease which prevent stabilization of hip and cause osteoarthritis (Benzioni *et al.*, 2008). Canine hip dysplasia (CHD) and osteoarthritis of the hip joint are now recognized as one of the most common orthopedic conditions in dogs (Rettenmaier *et al.*, 2002; Smith *et al.*, 2006; Zhang *et al.*, 2009). CHD is the abnormal development of the coxo-femoral joint that characterized by subluxation or complete luxation of the femoral head in younger patients and mild to severe degenerative joint disease in older patients (Rettenmaier *et al.*, 2002; Fossum *et al.*, 2013). The etiology of osteoarthritis of the hip joint in dogs was summarized by many authors (Smith *et al.*, 2006; Benzioni *et al.*, 2008) who stated that it might a degenerative joint disease (DJD) which is characterized by degeneration of the articular cartilage, hypertrophy of the bone margin and changes in the synovial membrane. The etiology of hip luxation in the affected dogs was traumatic in about 90% of cases (Özaydin *et al.*, 2003). The round ligament is usually

avulsed from the fovea capitis, the joint capsule is also ruptured in some cases (Dennyand Butterworth, 2000). Avascular necrosis (AVN) (Perthes Disease) of the femoral head is a developmental disturbance that generally affects young dogs of small breeds and produces ischemic necrosis of the femoral head resulting in joint malformation. The most common treatment is FHO (Parra *et al.*, 2017).

AVN of the femoral head is a serious complication after a femoral neck fracture. The blood supply to the femoral head might be hampered if the fracture cuts off the circumambient vessels (Tsuji, 1986). Many techniques are used for treating hip luxation, CHD, DJD, coxitis, and avascular necrosis as a salvage surgical procedure in dogs, in which the entire femoral head and part of the femoral neck are removed at an angle starting at the medial aspect of the greater trochanter such as femoral head and neck osteotomy (FHO) (Özaydin *et al.*, 2003; Trostel *et al.*, 2003; Lins *et al.*, 2009; Harper, 2017).

## MATERIALS AND METHODS

A total number of 12 male dogs of different breeds weighing 14-52 kg suffering from different hip joint disorders (Table 1) were admitted to the Vet. Surgery clinic, Faculty of Vet. Med. Zagazig University, Egypt, and from some different private pet animal clinics. FHO technique was performed by different methods

(osteotome (Fig. 1), oscillating saw (Fig. 2) and Gigli saw (Fig. 3).



Fig. 1. The used osteotome



Fig. 2. The used oscillating saw

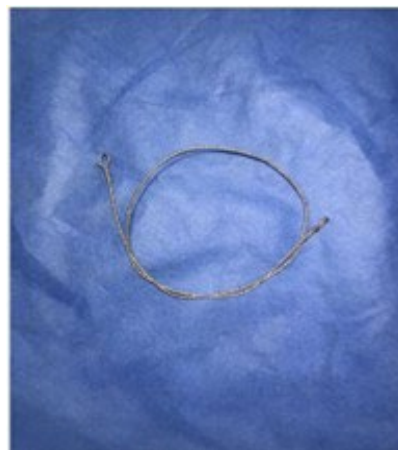

Fig. 3. The used Gigli saw

dose of 8.75 mg/kg BWT (1 ml/20kg bwt I/M). Sedation of animals was done by Xylazine hydrochloride (Xylaject 2% Adwia pharmaceutical Co. 10th Ramadan City. Egypt) at a dose of 0.5 mg/kg I/M (Morgan 1988). Then general anesthesia of animals by Propofol 1% B.Braun Germany 5 mg/kg BWT I/V (Sano *et al.*, 2003).

A craniolateral approach to the hip joint was performed. Incision of skin, subcutaneous tissue, blunt dissection between superficial gluteal and tensor facialata muscle running down toward the cranial edge of biceps femoris.

Blunt dissection between vastus lateralis and deep gluteal muscle. A partial tenotomy of the deep gluteal tendon was made. Incision of the joint capsule. Induction of luxation of the femoral head after cutting of round ligament. Elevation of the head of the femur by Hohman retractor. Cut of the femoral neck at a line parallel to greater trochanter by osteotome or oscillating saw or Gigli saw.

The femoral head and neck were excised. Removal of any bony remnants or splits at the site of operation was achieved. The joint capsule, muscles, subcutaneous tissue, and skin were sutured routinely.

*Post-operative care*

For managing surgical pain, flunixin meglumine (Finadyne® MSD) was injected once daily at a dose of 1mg/kg I/M (Johnson, 1996). Antibiotic was administered in the form of amoxicillin and clavulanic acid injection (Synulox® Zoetis USA), at a dose of 8.75

*FHO Femoral Head and Neck Ostectomy after Piermattei and Johnson (2004)*

The affected hip was aseptically prepared for surgery. Pre-operative antibiotic (Synulox® amoxicillin and clavulanic acid injection. Zoetis USA) was administered 2 hours before incision at a

Table 1. The admitted different cases and the applied FHO technique

Case no	Breed	Age	Sex	Weight	Diagnosis	Femoral head	Cause	Technique	material
1	Rottweiler	1.5 y	Male	38 kg	RT Hip luxation	Cr dorsal	Falling trauma	RT FHO	Gigli saw
2	Golden retriever	6 m	Male	18 kg	Bilateral hip dysplasia	RT + LT Cr dorsal	Hereditary	RT+LT FHO	Osteotome
3	Rottweiler	1.8	Male	40kg	LT Hip luxation + RT(AVN)	LT cr dorsal	Camel kick trauma	LT FHO	osteotome
4	German shepherd	8m	Male	22kg	Bilateral hip dysplasia	Cr dorsal	Hereditary	LT FHO	Osteotome
5	Saint Bernard	1.2y	Male	52kg	RT hip dysplasia	In acetabulum	Hereditary	RT FHO	Osteotome
6	German shepherd	6m	Male	16kg	LT hip dysplasia	Cr dorsal	Hereditary	RT FHO	Osteotome
7	German shepherd	1y	Male	31 kg	RT hip dysplasia	Cr dorsal	Hereditary	RT FHO	Gigli saw
8	Rottweiler	9y	Male	39kg	Bilateral OCD	In acetabulum	Aging	Bilateral FHO	Osteotome
9	Rottweiler	1.5y	Male	38 kg	RT hip dysplasia	Cr dorsal	Hereditary	RT FHO	Oscillating saw
10	Mongrel	5m	Male	14 kg	LT neck femur fracture	In acetabulum	Traumatic vehicle accident	LT FHO	The femoral neck was fractured
11	German shepherd	9m	Male	34kg	Bilateral hip dysplasia	Cr dorsal	Hereditary	RT FHO	Osteotome
12	Husky	7m	Male	18kg	LT hip luxation	Lodged in obturator foramen	Falling trauma	LT FHO	Oscillating saw

mg/kg BWT 1 ml/20 kg, BWT S/C once daily before surgery by 2 hours and followed by 6 days post-operative. Betadine 10% (Povidone iodine) was applied for wound antiseptis. Exercise was restricted for four weeks

Elizabethan collar was placed around the head of the animal for preventing licking or opening the wound.

#### Follow-up

Each case was examined clinically and radiographically by Toshiba Rotanode (POX-300 BT, Japan) radiographic machine with an exposure factor of 65 KV and 6 mA.s.,

after surgery then every week for 12 weeks. Follow up included examination and care of pain, wound infection, lameness, crepitus, range of motion of affected joint. Furthermore, plain x-ray ventrodorsal (VD) position was done under sedation with Xylazine hydrochloride (Xylaject 2% Adwia pharmaceutical Co. 10th Ramadan City. Egypt) At a dose of 0.5mg/kg I/M (Morgan 1988)

## RESULTS

Admitted cases of CHD (7 cases) were expected to be caused by a combination of hereditary and environmental factors where abnormal development of the hip joint was observed. No evidence of complications associated with the current surgical technique. All cases started ground toe touch after one week. After 3 weeks, start weight bearing with nonpainful lameness. After 5 weeks, mild nonpainful lameness with weight bearing. After the 12<sup>th</sup> week, no lameness but slight abnormal gait. There was no

crepitation during clinical exams after surgery. Normal locomotion angle during the exam., and no palpable difference between normal leg and treated leg. After 6 months post operation, excellent limb functions without lameness. Radiographically there was no osteophyte in all cases done by osteotome (Fig. 4) or cases done by the oscillating saw (Fig. 5). But the presence of a small part of the neck of the femur was noticed in the two cases done by Gigli saw as presented in Fig. 6.

## DISCUSSION

In the current research, CHD was caused by a combination of hereditary and environmental factors as agreed by Mäki *et al.* (2002), and Nouh *et al.* (2014) who stated that CHD is a hereditary malformation that develops during periods of rapid growth. Each of these dysplasias can cause arthritis and/or severely deformed joints, disabling the dog Hip dysplasia has been reported as a quantitative trait occurring in numerous breeds. All cases with CHD in this research don't have a history of trauma that prove that it was a hereditary disease and all cases from different breeds indicate that CHD is not restricted to a certain breed. Slatter (1993) stated that hip luxation mostly occurs craniodorsal that result was in accordance with this study as 2 of 3 hip luxation cases in femoral head position were craniodorsal. Fossum (1997) reported that luxation of the femoral head and lodged in the obturator foramen is usually due to falling trauma, which in accordance with the obtained findings as one of two dogs suffering from hip luxation of the femoral head luxate and lodged in obturator foramen. (Harper, 2017) stated that FHO is a salvage surgical procedure in dogs. Active use of the limb may take over 1 month and rehabilitation times of 6 months or more are common. This result was accepted in this study as all cases after

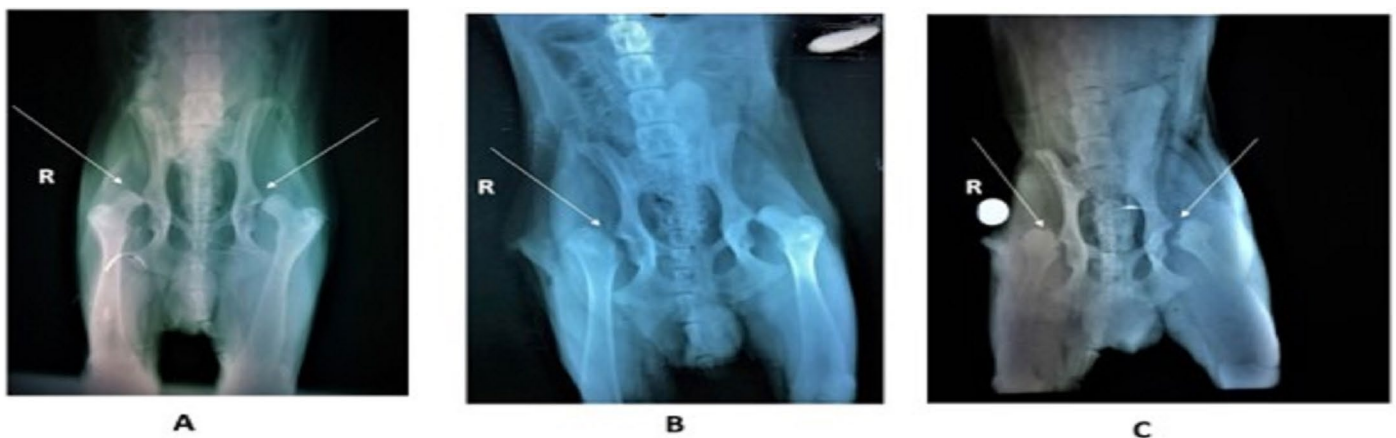

Fig. 4. Hip dysplasia pre and post-operative using osteotome; (A) showing hereditary bilateral hip dysplasia in 6 months male golden retriever dog; (B) showing the postoperative FHO for the right hip; (C) after 3 months post-operative FHO for the left hip.

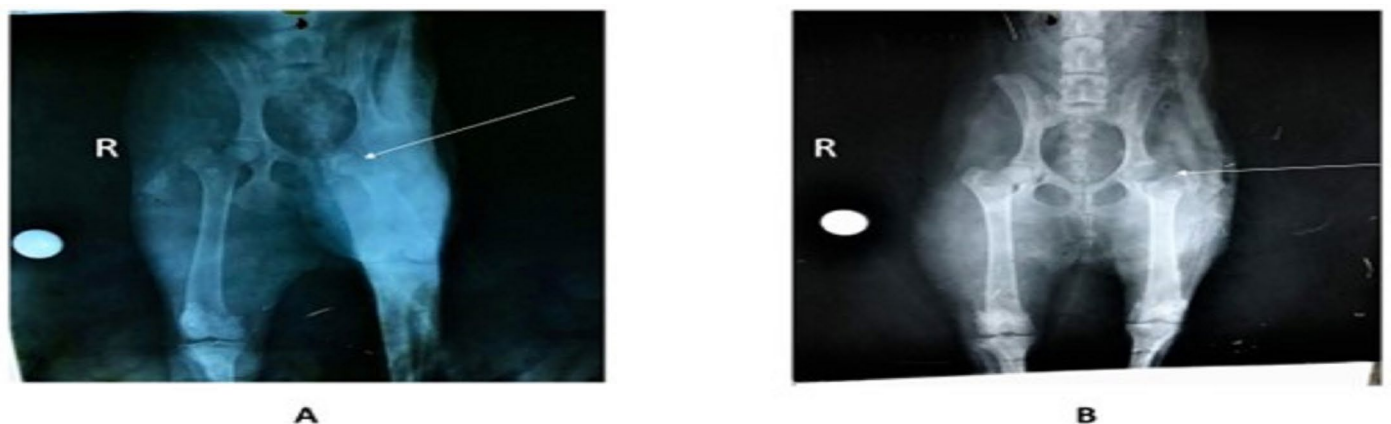


Fig. 5. Hip luxation pre and post-operative using an oscillating saw showing a 7 months male husky dog suffering from left hip luxation due to falling trauma and the femoral head lodged in obturator foramen; (B) post-operative FHO using an oscillating saw.

