

# Effect of the Subconjunctival Injection of Oxytetracycline 5% on the Induced Alkali Burn Corneal Ulcer in Rabbits

Mohammed A.H. Abdelhakiem<sup>1\*</sup>, Aya Hamdy<sup>1</sup>, Khaled M.A. Hassanien<sup>2</sup>, Magda M. Ali<sup>1</sup>

<sup>1</sup>Department of Surgery, Anesthesiology and Radiology, Faculty of Veterinary Medicine, Assiut University, Assiut, 71526, Egypt.

<sup>2</sup>Department of Pathology and Clinical pathology, Faculty of Veterinary Medicine, Assiut University, Assiut, 71526, Egypt.

## \*Correspondence

Mohammed A.H. Abdelhakiem  
Department of Surgery, Anesthesiology and Radiology, Faculty of Veterinary Medicine, Assiut University, Assiut, 71526, Egypt.  
E-mail address: hamdsurgery@aun.edu.eg

## Abstract

Tetracycline had proven to be effective in the management of the different types of corneal ulcers. It has antimicrobial activity as well as anti-collagenase effect. Therefore, the present study was conducted to investigate the effect of oxytetracycline 5% on the alkali burn corneal ulcer after its injection subconjunctivally. Ten healthy New Zealand albino rabbits were divided into equal groups (control and treatment). They were examined carefully before induction of the ulcer using in 1% NaOH in the right eye. A 0.5 ml of oxytetracycline 5% was injected in the subconjunctival space weekly for 5 consecutive weeks. The eye was examined weekly clinically and by fluorescein staining dye just before the injection of oxytetracycline. At the end of the study, the rabbits were euthanized and the eyes were harvested for histological and electron microscopic examinations. The results revealed there were no significant variations between the control and treatment groups except for prevention of bacterial colonization on the ulcerated corneal surface in the oxytetracycline group. The conclusion of the present study was the subconjunctival injection of oxytetracycline was not efficient for management of alkali burn corneal ulcers, but it could be used as adjunctive treatment for control and prevention of bacterial growth on the ulcerated corneal surface.

## KEYWORDS

Anti-collagenolytic, Corneal ulceration, Subconjunctival, Oxytetracycline 5%, Alkali

## INTRODUCTION

One of the most ocular lesions is chemical burns that occur mostly accidentally and result in severe corneal tissue damage. Alkali burns are among the most chemicals devastating of ocular injuries. Sterile corneal ulceration often occurs following chemical trauma or as a manifestation of ocular or systemic inflammatory disease (Kenyon, 1982). While the cellular and biochemical processes of corneal ulceration are complex, the tissue and leukocyte collagenases may have a key role in the common final pathway of corneal ulceration (Slansky *et al.*, 1968; Gnädinger *et al.*, 1969; Brown *et al.*, 1969, 1970; Pfister *et al.*, 1971; Brown, 1975; Berman *et al.*, 1979; Foster *et al.*, 1979; Kenyon *et al.*, 1979; Gordon *et al.*, 1980; Kenyon, 1982).

The main target of many therapeutics is to inhibit collagenase activity. Clinical success has been achieved with only a small number of these treatments. Oxytetracycline has demonstrated a remarkable anti-collagenase effect in rats, rabbits, and humans (Golub *et al.*, 1983, 1984, 1985; Perry and Golub, 1984). It appears that Oxytetracycline's antimicrobial action is independent of its collagenolytic effects. As a result, even noninfected corneal ulcer cases were successfully treated with systemic tetracycline (Perry and Golub, 1985). It was hypothesized due to the topical and systemic effect of oxytetracycline in treatment and prevention of corneal ulcers (Seedor *et al.*, 1987; Chandler *et al.*, 2010), the

subconjunctival injection of it may have a favorable and promoting healing effect on corneal ulcers. The mean time for healing corneal ulcers was also expected to be shorter due to the drug accumulating for a long time in the subconjunctival space and slowly diffusing out. Therefore, the present study aimed to investigate the effect of Oxytetracycline 5% in the treatment of alkali burn corneal ulcers in rabbits after its subconjunctival injection.

## MATERIALS AND METHODS

Ten healthy New Zealand albino rabbits (five males and five non-pregnant non-lactating females) were included in this study. The age varied from 7-8 months (mean±SE=7.55±0.09) and the body weight ranged from 1700-2500 grams (mean±SE=1952.26±37.38). The experiment was performed under the standards of the ethical committee of the national ethical committee of the Faculty of Veterinary Medicine, Assiut University, Assiut, Egypt (the ethical approval number is aun/Vet/1/0001). A thorough examination of all rabbits was conducted to identify and exclude any animals with ophthalmic lesions. The globe was inspected for its normal shape and position, ocular discharges, ocular movements and normal eye reflexes and response. The rabbits were anesthetized after the intramuscular injection of 5 mg/kg of xylazine HCL 2% (Xyla-Ject, ADWIA Co., SAE, Egypt) and 25 mg/kg Ketamine HCL 5% (Ketamine hydrochloride, Ro-

texmedica, Trittau, Germany). A corneal ulcer was induced in the right eye of all animals after touching a sterile small cotton swab soaked in 1% NaOH (It was prepared in the laboratory of the Chemistry Department, Faculty of Science, Assiut University, Assiut, Egypt) to the center of the cornea for 60 seconds. After that, the ocular surface was irrigated with physiological saline (0.9% NaCl) for two minutes. A fluorescein dye test was used to confirm and assure ulcer formation (Hassan et al., 2021; Hosny et al., 2022).

These animals were divided into two groups each of five rabbits; Group I (Control group) received a subconjunctival injection of 0.5 ml of the normal saline solution once weekly for five successive weeks. Group II (Treatment group) received a subconjunctival injection of 0.5 ml of oxytetracycline 5% (oxytetracycline 5%; NasrPharma-Vetwic, Egypt) once-weekly for five successive weeks. One day after the last application all animals were euthanized by rapid intravenous injection of 2.5% thiopental sodium (Anapental 500 mg; EPICO, Egypt) into the cephalic vein in a dose of 35mg/kg.b.w. The examination of the eye was carried out just before every injection. Naked-eye examinations of each rabbit's eye were performed on days 8, 15, 22, and 29 and 36 by two observers. They were inspected for the presence of lacrimation, pus formation, neovascularization, the size of ulcer, corneal opacity and perforation. The lacrimation was measured as mild, moderate and severe according the time consumed for saturation of shrimmer paper. The different grades were as following: 0: normal secretion of tears (0-11 mm/minute); 1: incomplete saturation of the paper within 1 minute (mild degree of lacrimation); 2: complete saturation within 1 minute (moderate), and 3: complete saturation of paper in less than 1 minute (severe) (Abrams et al., 1990). Corneal neovascularization was scored from 0 to 3 ( Sotozono et al., 2007; Basu et al., 2018) where 0 = no neovascularization, 1 = confined to the limbus of the cornea, 2 = extending up to the margin of the pupil, and 3 = extending beyond the margin of the pupil into the central cornea. The size of ulcer was monitored to determine whether it is increased or decreased. The diameter of corneal ulcer (in mm) was measured using the ImageJ software (ImageJ 4.48v software, National Institutes of Health, USA). Corneal opacity grading was performed as follows: grade 0= clear or a trace haze; grade 1= mild opacity, grade 2= moderately dense opacity partially obscuring the details of the iris, and grade 3= severely dense opacity obscuring the details of the intraocular structure (Fantes et al., 1990).

*Fluoresceine Staining Test*

The test was carried out after an ophthalmic examination just before the treatment as the clinical examinations on days 8, 15, 22, 29 and 36. One drop of 2% fluorescein dye (Fluorescein Sodium 2% w/v; Bausch and Lomb (Australia) Pty. Ltd. G/F 16 Giffnock, Macquarie Park NSW 2113 Australia) was applied to the eye and left for one min. Afterward, sterile normal saline of 0.9% was used to rinse the eye and remove the excess stain (Petroutsos and Pouliquen, 1984).

*Histopathological examination*

At the end of the study, tissue samples from the cornea were fixed in 10 % neutral buffered formalin. Then dehydration by ascending grades of alcohol, clearing by xylene, and embedding in paraffin. Sectioning of the tissue was 4-5 microns in thickness then stained with hematoxylin and eosin stains (H&E) (Banchroft et al., 1996) for histopathological evaluation.

Table 1. Different clinical findings in the control and treatment groups at different examination times (weeks), additionally the difference between the 1st and 5<sup>th</sup> week.

Inclusion criteria	Treatment group	Control	P value
<b>Corneal opacity</b>			
Week 1	0.4±0.55	1.0±1.0	0.327
Week 2	2±1	1.33±1.15	0.439
Week 3	1.2±1.3	2±1.73	0.433
Week 4	1.0±1.22	2±1.73	0.43
Week 5	1.0±1.22	2±1.73	0.43
<i>P2 WEEK1 VS WEEK5</i>	0.414	0.18	
<b>Corneal neovascularization</b>			
Week 1	0.0±0.0	0.0±0.0	1
Week 2	0.6±0.89	0.67±0.58	0.744
Week 3	1.6±1.52	1.67±0.58	0.877
Week 4	3.0±0.0	2.33±1.15	0.197
Week 5	2.4±1.34	2.33±1.15	0.845
<i>P2 WEEK1 VS WEEK5</i>	0.046*	0.102	
<b>Lacrimation</b>			
Week 1	0.6±1.34	1.67±1.53	0.302
Week 2	0.8±1.3	1.33±1.15	0.522
Week 3	0.8±1.3	1.33±0.58	0.273
Week 4	0.8±1.3	1.67±1.15	0.207
Week 5	0.8±1.3	2.0±1.0	0.164
<i>P2 WEEK1 VS WEEK5</i>	0.317	0.317	
<b>Ulcer measurement</b>			
Week 1	6.92±1.15	4.6±1.95	0.101
Week 2	7.46±8.18	1.87±2.42	0.18
Week 3	6.04±7.1	3.8±1.31	0.881
Week 4	7.48±7.71	1.43±1.25	0.368
Week 5	5.6±7.68	6.1±5.03	0.647
<i>P2 WEEK1 VS WEEK5</i>	0.686	1	
<b>Presence of pus</b>			
Week 1	0.0±0.0	1.0±1.0	0.051
Week 2	0.0±0.0	0.33±0.58	0.197
Week 3	0.4±0.55	1.0±1.0	0.327
Week 4	0.0±0.0	0.67±0.58	0.049*
Week 5	0.0±0.0	0.33±0.58	0.197
<i>P2 WEEK1 VS WEEK5</i>	1	0.317	
<b>Perforation</b>			
Week 1	0.0±0.0	0.0±0.0	1
Week 2	0.0±0.0	0.0±0.0	1
Week 3	0.2±0.45	0.33±0.58	0.693
Week 4	0.2±0.45	0.33±0.58	0.693
Week 5	0.2±0.45	0.33±0.58	0.693
<i>P2 WEEK1 VS WEEK5</i>	0.317	0.317	

Values are expressed as mean±SE  
P1 calculated by Mann-whitney U test, p2 calculated by Wilcoxon t-test. \*: Statistically significant difference (p<0.05); \*\*: Highly statistically significant difference (p<0.01); P1: Comparison between T & Control groups for each week; P2: Comparison between week 1 and week 5 for each group.

*Scanning electron microscopy*

For scanning electron microscopy, representative specimens

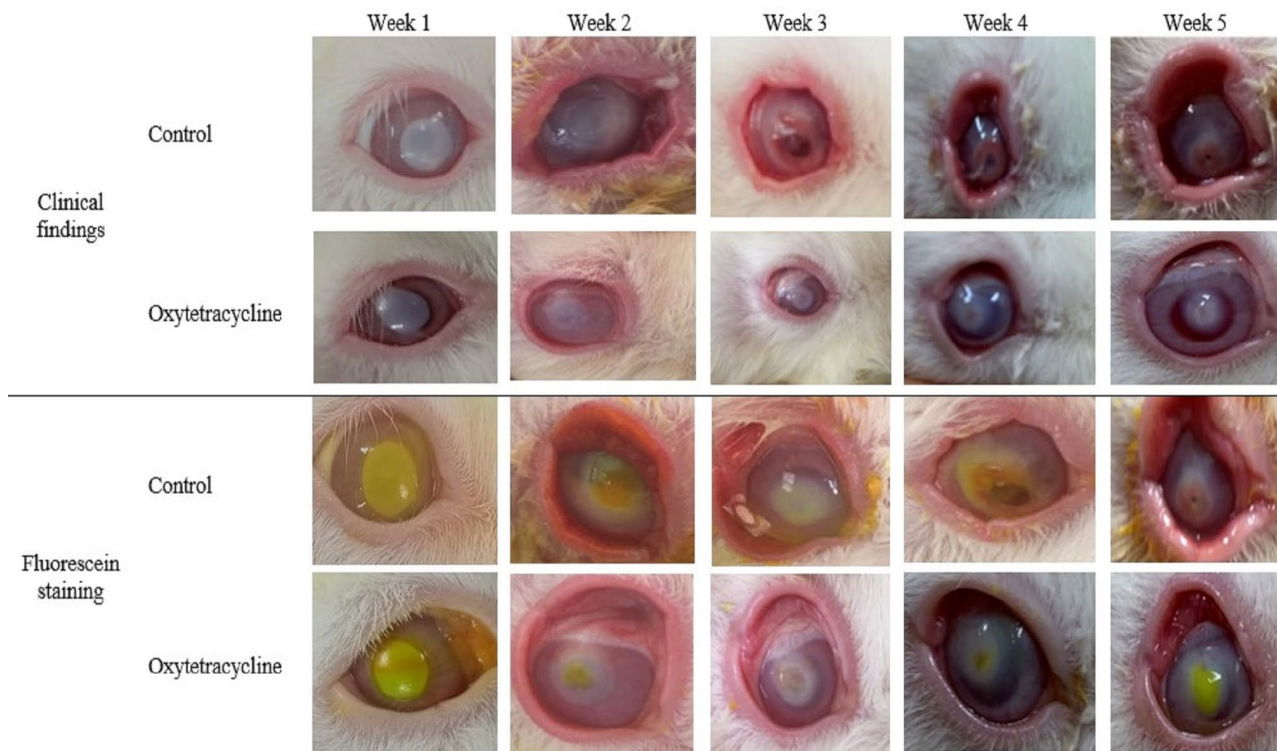


Figure 1. The changes of the eye after induction of ulcer by 1% NaOH in control and oxytetracycline groups. The corneal opacity is present along the five weeks in both groups. The perforation of the cornea started from the 3rd week and was clear in the control group. The fluorescein dye uptake was more obvious in the first two weeks and was not high after that due to perforating cornea especially in the control.

from the cornea were immediately washed with normal saline. Subsequently, fixed in a mixture of 2.5% paraformaldehyde and 5% glutaraldehyde in 0.1 M. sodium phosphate buffer with a pH of 7.3 at 4°C for 24 h. then washed with 0.1 M sodium phosphate buffer with a pH of 7.3. The samples were dehydrated using ascending series of ethanol 30, 50, 70, and 90% for two hours, 100% for two days., and then in amyl acetate for two days. Critical point drying was applied to the samples by using liquid carbon dioxide. Each sample was stuck on metallic blocks using silver paint. By using gold sputter coating apparatus, samples were evenly gold coated at a thickness of 15 nm. samples were examined by using a JEOL (JSM 5400 LV) scanning electron microscope 15- 25 kV and photographed in the electron microscope unit, at Assiut University, Egypt (Bozzola and Russell, 1991). Digital coloring scanning electron microscopic images. The scanning electron microscopic images were digitally colored using the Photo Filter 6.3.2 program to recognize different types of cells and structures.

**Statistical analysis**

Statistical analysis was done using Kolmogorov-Smirnov and Shapiro-Wilk tests where the numerical data were explored for normality by checking the distribution of data and using tests of normality. The parameters were not normally distributed. Data were presented as mean±standard deviation (SD). Mann Whitney U test was used to compare two groups in non-related samples. Wilcoxon’s t-test was used to compare week one to week five in each group. The significance level was set at P < 0.05. Statistical analysis was performed with IBM® SPSS® Statistics Version 26 for Windows.

**RESULTS**

**Clinical findings**

In the control group, the presence of ophthalmic disorders

especially corneal opacity, corneal neovascularization, and perforation was noticeable in the first week, gradually increasing but not significantly to reach a maximum in the third, fourth, and fifth weeks (Figs. 1,2,3). Other signs such as lacrimation, pus formation, and size of the ulcer were fluctuated between the weeks but also not substantial (Fig. 3). There were no clear differences between animals in the same group (Table 1). Regarding the oxytetracycline group, there were non-significant fluctuations in corneal opacity, corneal neovascularization, and size of the ulcer. The lacrimation was steady from the 2nd week till the end of the study. The pus formation stopped in the fourth and fifth weeks. The perforation appeared in the 3rd week. There was a significant increase in corneal neovascularization in the fifth week relative to the 1st week in the oxytetracycline group (P=0.046). As well as the pus formation was significantly increased in the control group relative to the other group in the fourth week (P= 0.049). Neither group’s fluorescein dye uptake changed from day one to the end of the study, which confirmed the clinical findings. (Table 1, Figs. 1, 2,3).

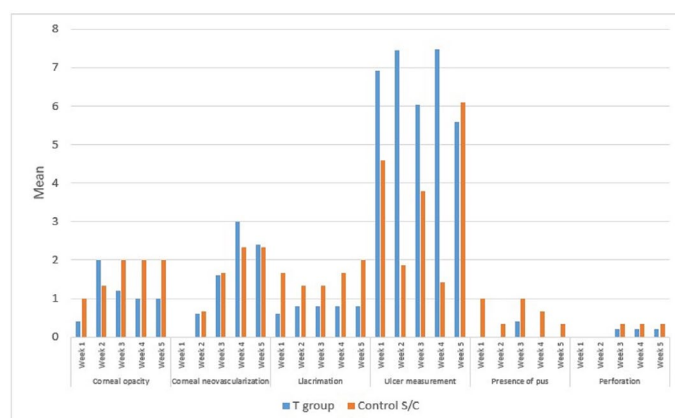
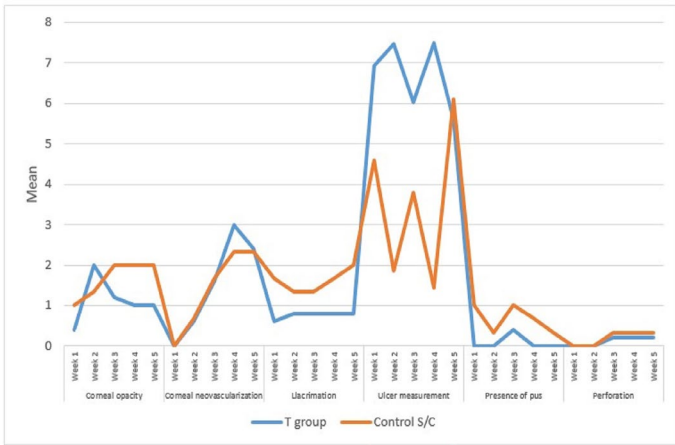


Figure 2. The different clinical findings at different weeks in the control and oxytetracycline groups.



*Histopathological findings*

The control group showed necrosis and desquamation of epithelium in addition to multiple ulcerated areas covered with colonies of bacteria were seen. Due to the edema and infiltrative inflammatory cells, the stroma appeared larger than normal. Descemet’s membrane was damaged (Fig. 4 A-C). Oxytetracycline treated group showed necrosed corneal epithelium with ulcer formation. Edema of stroma, swelling of the collagenous fibers, and damage of the Descemet’s membrane (Fig. 4 D, E).

*Scanning electron microscopy*

The scanning electron microscopy demonstrated multiple ulcerations and denuded epithelium in the control group. Bacterial colonies within the ulcerated areas and widening and en-

Figure 3. The fluctuations of the clinical findings along 5 weeks in the control and oxytetracycline groups.

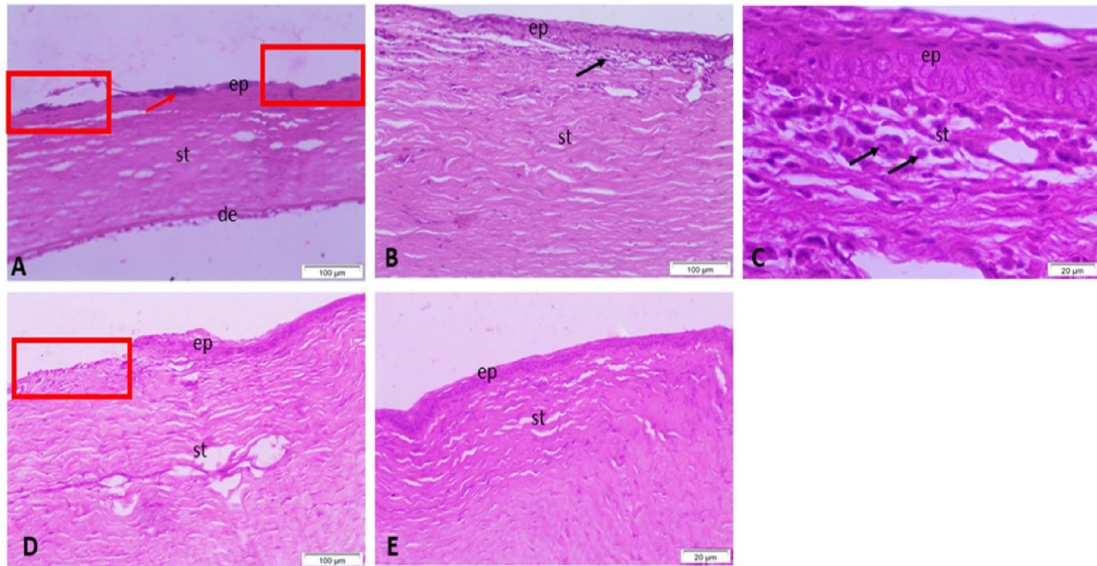


Figure 4. Representative micrograph of the cornea stained by HE stains. A-C) Control group treated by subconjunctival injection showing necrosed epithelium (ep), stroma (st), damaged Descemet’s membrane (de), ulcer (red rectangles), colonies of bacteria (red arrow) and inflammatory cells (black arrows). D, E). Oxytetracycline treated group by subconjunctival injection showing necrosed epithelium (ep), edema of stroma (st), damaged descemet layer (de) and ulcer (red rectangles).

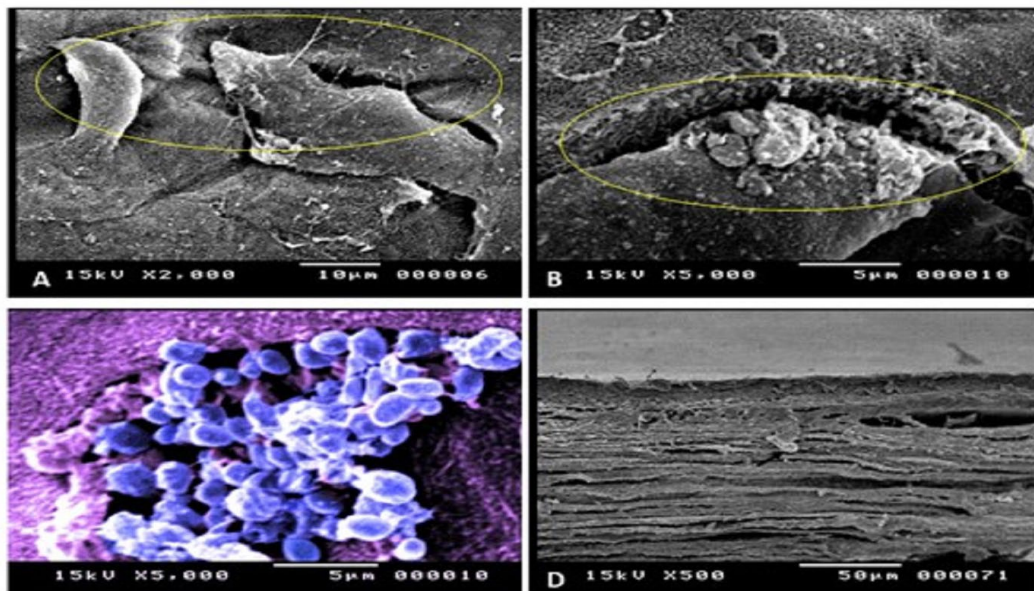


Figure 5. Scanning electron micrograph of the cornea in control group treated by subconjunctival injection showed ulceration and denuded epithelium (A,B). Digitally colored Scanning electron micrograph showing colonies of bacteria (blue color) (C). Stroma revealed widening and presence of leucocyte (arrow) (D).

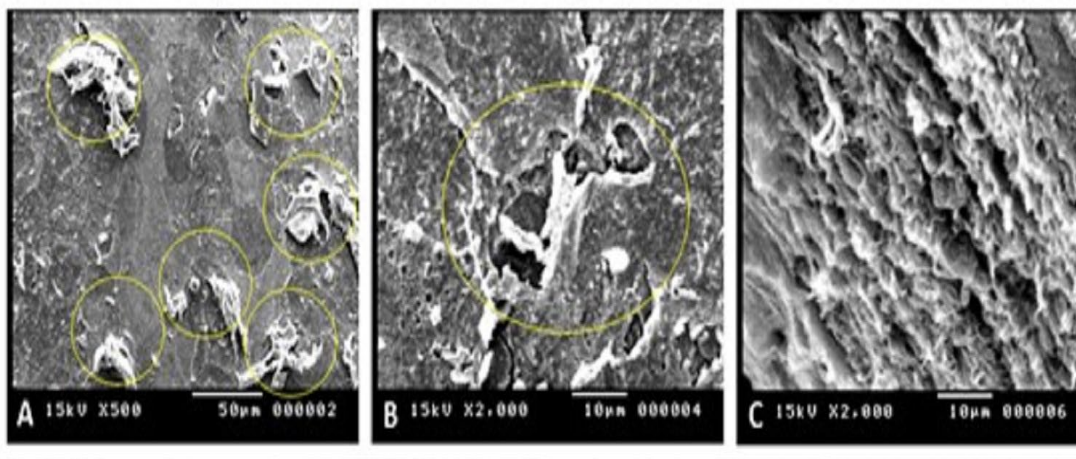


Figure 6. Scanning electron micrograph of the cornea in Oxytetracycline treated group showed multiple ulceration in the corneal surface (yellow circles) and widening of stroma (A-C).

largement of the stroma with leucocytic cellular infiltration were noticed (Fig. 5). Multiple ulcers on the corneal surface, expansion of the stroma, but no bacteria or leucocytes were seen in the oxytetracycline-treated group (Fig. 6 A-C).

## DISCUSSION

The present study aimed to investigate the efficacy of a subconjunctival injection of 5% oxytetracycline in the treatment of alkali burn corneal ulcers. The use of oxytetracycline in the form ophthalmic ointment has proven to be efficient as adjunctive treatment in refractory corneal ulcers in dogs (Chandler *et al.*, 2010). As well as the intra-muscular using of large doses (50 mg/kg/day for 28 days) of tetracycline was more effective in preventing ulceration that was induced by 1N sodium hydroxide (Seedor *et al.*, 1987). Nevertheless, its use through the subconjunctival route did not yield the expected and hypothesized results. The clinical and histopathological findings of the present study did not show any clear significant difference between the treatment and the control groups except the absence of bacterial colonization that cover the ulcers. The oxytetracycline prevented the growth and multiplication of microorganisms on the surface of ulcerated cornea which was displayed by histopathological findings and scanning electron microscopy and was clear on clinical findings (decrease of pus formation). This is attributed to the antibacterial effect of the oxytetracycline (Eastman *et al.*, 1998). The use of oxytetracycline in treatment of bacterial ophthalmic lesions was approved in previous studies (Hoshiwara *et al.*, 1973; George *et al.*, 1988). The results of the present study revealed no improvement in the signs of inflammation, ulcer measurements or epithelium regeneration after tetracycline treatment. These findings were not in consistent with those were obtained by Ralph (2000). In that study, the author recommended the combined use of tetracycline orally and topically to overcome the moderate and severe ocular chemical injuries that may destroy the cornea. He attributed that to the antimicrobial properties of tetracycline, as they inhibit matrix metalloproteinases through inhibition of neutrophil collagenase gene expression and gelatinase activity, suppression of 1-antitrypsin degradation, As well as, it scavenges reactive oxygen species. Although several studies advocated the use of tetracycline for management of infectious and non-infectious corneal ulcers (Perry and Golub, 1984, 1985; Seedor *et al.*, 1987; George *et al.*, 1988; Eastman *et al.*, 1998; Ralph, 2000; Chandler *et al.*, 2010), the results of this study did not support these previous studies. These differences could be ascribed to some factors such as; 1) The route of injection of oxytetracycline: previous studies used oral and/or intramuscular routes unlike the subconjunctival injection in the present study. 2) The frequency of drug administration: in the present study the

oxytetracycline was injected into the subconjunctival space one weekly for 5 weeks, but the other studies used the tetracycline daily for different durations according to the methodology of these studies. 3) The molecular weight of the oxytetracycline HCL 5%. According to Papich and Riviere (2018), the national library of medicine (national center for biotechnology information <https://pubchem.ncbi.nlm.nih.gov/compound/Oxytetracycline>) and Sigma-aldrich company (<https://www.sigmaaldrich.com/DE/de/product/sigma/o5875>) the molecular weight of oxytetracycline HCL is 460.44 amu (atomic mass unit). In accordance with the results of the present study, it was noticed that the corneal perforation started on the 3rd week from the induction time of ulcer. Therefore, the effect of sodium hydroxide 1N was not transient, but it had a persistent progressive effect. This means that the alkaline media due to NaOH was prevailing which might hinder the effect of oxytetracycline. Although traces of tetracycline molecules reach the ophthalmic tissue after oral or systemic administration, it promoted and enhanced the corneal ulcer healing. This is due to tetracycline is not restricted by protein binding but are widely distributed throughout most tissues of the body, including intracellular sites (Papich and Riviere, 2018).

## CONCLUSION

The single weekly subconjunctival injection of oxytetracycline 5% for 5 consecutive weeks was not effective for the treatment of alkali burn induced corneal ulcer in rabbits. But it was effective for prevention of bacterial colonization on the ulcerated corneal surface. Therefore the subconjunctival injection of oxytetracycline 5% is recommended to be used as adjunctive treatment with the main essential agents used for management of the alkali burn corneal ulcers.

## ACKNOWLEDGMENTS

The authors would like to thank the departments of Surgery, Pathology, Faculty of Veterinary Medicine, the unit of Electron microscope, and Assiut University for their support and facilitation of this work.

## CONFLICT OF INTEREST

The authors declare that they do not have any known competing financial interests or personal relationships that could have appeared to influence the work reported in this manuscript.

## REFERENCES

Abrams, K.L., Brooks, D.E., Funk, R.S., Theran, P., 1990. Evaluation of the

- Schirmer tear test in clinically normal rabbits. *American Journal of Veterinary Research* 51, 1912–1913.
- Banchroft, J.D., Stevens, A., Turner, D.R., 1996. *Theory and practice of histological techniques* (fourth. Churchil Livingstone, New York, London, San Francisco, Tokyo.
- Basu, S., Mohan, S., Bhalekar, S., Singh, V., Sangwan, V., 2018. Simple limbal epithelial transplantation (SLET) in failed cultivated limbal epithelial transplantation (CLET) for unilateral chronic ocular burns. *The British Journal of Ophthalmology* 102, 1640–1645. <https://doi.org/10.1136/bjophthalmol-2017-311506>
- Berman, M., Leary, R., Gage, J., 1979. Collagenase from corneal cell cultures and its modulation by phagocytosis. *Investigative Ophthalmology Visual Science* 18, 588–601.
- Bozzola, J., Russell, L., 1991. *Electron microscopy principles and techniques for biologi*. Jones and Bartlitt publishers 20 park ppls, Boston Ma 02116.
- Brown, S.I., 1975. Mooren's ulcer. *Histopathology and proteolytic enzymes of adjacent conjunctiva*. *The British Journal of Ophthalmology* 59, 670–674. <https://doi.org/10.1136/bjo.59.11.670>
- Brown, S.I., Weller, C.A., Akiya, S., 1970. Pathogenesis of ulcers of the alkali-burned cornea. *Archives of Ophthalmology* (Chicago, Ill.: 1960) 83, 205–208. <https://doi.org/10.1001/archophth.1970.00990030207014>
- Brown, S.I., Weller, C.A., Wassermann, H.E., 1969. Collagenolytic activity of alkali-burned corneas. *Archives of Ophthalmology* (Chicago, Ill.: 1960) 81, 370–373. <https://doi.org/10.1001/archophth.1969.00990010372015>
- Chandler, H.L., Gemensky-Metzler, A.J., Bras, I.D., Robbin-Webb, T.E., Saville, W.J.A., Colitz, C. M. H., 2010. In vivo effects of adjunctive tetracycline treatment on refractory corneal ulcers in dogs. *Journal of the American Veterinary Medical Association* 237, 378–386. <https://doi.org/10.2460/javma.237.4.378>
- Eastman, T.G., George, L.W., Hird, D.W., Thurmond, M.C., 1998. Combined parenteral and oral administration of oxytetracycline for control of infectious bovine keratoconjunctivitis. *Journal of the American Veterinary Medical Association* 212, 560–563.
- Fantes, F.E., Hanna, K.D., Waring, G.O., Pouliquen, Y., Thompson, K.P., Savoldelli, M., 1990. Wound healing after excimer laser keratomileusis (photorefractive keratectomy) in monkeys. *Archives of Ophthalmology* (Chicago, Ill.: 1960) 108, 665–675. <https://doi.org/10.1001/archophth.1990.01070070051034>
- Foster, C.S., Kenyon, K.R., Greiner, J., Greineder, D.K., Friedland, B., Alansmith, M.R., 1979. The immunopathology of Mooren's ulcer. *American Journal of Ophthalmology* 88, 149–159. [https://doi.org/10.1016/0002-9394\(79\)90459-8](https://doi.org/10.1016/0002-9394(79)90459-8)
- George, L., Mihalyi, J., Edmondson, A., Daigneault, J., Kagonyera, G., Willits, N., Lucas, M., 1988. Topically applied furazolidone or parenterally administered oxytetracycline for the treatment of infectious bovine keratoconjunctivitis. *Journal of the American Veterinary Medical Association* 192, 1415–1422.
- Gnäding, M.C., Itoi, M., Slansky, H.H., Dohlman, C.H., 1969. The role of collagenase in the alkali-burned cornea. *American Journal of Ophthalmology* 68, 478–483. [https://doi.org/10.1016/0002-9394\(69\)90718-1](https://doi.org/10.1016/0002-9394(69)90718-1)
- Golub, L.M., Lee, H.M., Lehrer, G., Nemiroff, A., McNamara, T. F., Kaplan, R., Ramamurthy, N.S., 1983. Minocycline reduces gingival collagenolytic activity during diabetes. Preliminary observations and a proposed new mechanism of action. *Journal of Periodontal Research* 18, 516–526. <https://doi.org/10.1111/j.1600-0765.1983.tb00388.x>
- Golub, L.M., Ramamurthy, N., McNamara, T.F., Gomes, B., Wolff, M., Casino, A., Kapoor, A., Zambon, J., Ciancio, S., Schneir, M., 1984. Tetracyclines inhibit tissue collagenase activity. A new mechanism in the treatment of periodontal disease. *Journal of Periodontal Research* 19, 651–655. <https://doi.org/10.1111/j.1600-0765.1984.tb01334.x>
- Golub, L.M., Wolff, M., Lee, H.M., McNamara, T.F., Ramamurthy, N.S., Zambon, J., Ciancio, S., 1985. Further evidence that tetracyclines inhibit collagenase activity in human crevicular fluid and from other mammalian sources. *Journal of Periodontal Research* 20, 12–23. <https://doi.org/10.1111/j.1600-0765.1985.tb00405.x>
- Gordon, J.M., Bauer, E.A., Eisen, A.Z., 1980. Collagenase in human cornea: Immunologic localization. *Archives of Ophthalmology* (Chicago, Ill.: 1960) 98, 341–345. <https://doi.org/10.1001/archophth.1980.01020030337022>
- Hassan, M.A., AboZakaib, F., Nasr El-din, N., Elzeftawy, M., Nasif, M., El-Sherif, M., 2021. Effect of Platelet Rich Plasma on Corneal Alkali Burn Ulcer in Rabbits. *Journal of Current Veterinary Research* 3, 73–83. <https://doi.org/10.21608/jcvr.2021.199438>
- Hoshiwara, I., Ostler, H.B., Hanna, L., Cignetti, F., Coleman, V.R., Jawetz, E., 1973. Doxycycline treatment of chronic trachoma. *JAMA* 224, 220–223.
- Hosny, O.H., Abd-Elkareem, M., Ali, M.M., Ahmed, A.F., 2022. Effect of Autologous Serum Derived from Advanced Platelet-rich Fibrin on the Healing of Experimentally-induced Corneal Ulcer in Donkeys (*Equus asinus*). *Journal of Advanced Veterinary Research* 12, Article 1.
- Kenyon, K.R., 1982. Decision-making in the therapy of external eye disease: Noninfected corneal ulcers. *Ophthalmology* 89, 44–51. [https://doi.org/10.1016/s0161-6420\(82\)34860-5](https://doi.org/10.1016/s0161-6420(82)34860-5)
- Kenyon, K. R., Berman, M., Rose, J., Gage, J., 1979. Prevention of stromal ulceration in the alkali-burned rabbit cornea by glued-on contact lens. Evidence for the role of polymorphonuclear leukocytes in collagen degradation. *Investigative Ophthalmology Visual Science*, 18(6), 570–587.
- Papich, M., Riviere, J., 2018. *Tetracycline Antibiotics*. In M. Papich J. Riviere, *Veterinary Pharmacology and Therapeutics* (10th ed., pp. 858–876. Hoboken, NJ : John Wiley Sons Inc.,
- Perry, H. D., Golub, L. M., 1984. Beneficial effect of systemic tetracycline therapy in the treatment of noninfected corneal ulcers. *Cornea*, 3(1), 75.
- Perry, H. D., Golub, L. M., 1985. Systemic tetracyclines in the treatment of noninfected corneal ulcers: A case report and proposed new mechanism of action. *Annals of Ophthalmology*, 17(12), 742–744.
- Petroutsos, G., Pouliquen, Y., 1984. Effect of ascorbic acid on ulceration in alkali-burned corneas. *Ophthalmic Research*, 16(4), 185–189. <https://doi.org/10.1159/000265322>
- Pfister, R. R., McCulley, J. P., Friend, J., Dohlman, C. H., 1971. Collagenase activity of intact corneal epithelium in peripheral alkali burns. *Archives of Ophthalmology* (Chicago, Ill.: 1960), 86(3), 308–313. <https://doi.org/10.1001/archophth.1971.01000010310014>
- Ralph, R. A., 2000. Tetracyclines and the treatment of corneal stromal ulceration: A review. *Cornea*, 19(3), 274–277. <https://doi.org/10.1097/00003226-200005000-00003>
- Seedor, J. A., Perry, H. D., McNamara, T. F., Golub, L. M., Buxton, D. F., Guthrie, D. S., 1987. Systemic tetracycline treatment of alkali-induced corneal ulceration in rabbits. *Archives of Ophthalmology* (Chicago, Ill.: 1960), 105(2), 268–271. <https://doi.org/10.1001/archophth.1987.01060020122043>
- Slansky, H. H., Freeman, M. I., Itoi, M., 1968. Collagenolytic activity in bovine corneal epithelium. *Archives of Ophthalmology* (Chicago, Ill.: 1960), 80(4), 496–498. <https://doi.org/10.1001/archophth.1968.00980050498018>
- Sotozono, C., Ang, L. P. K., Koizumi, N., Higashihara, H., Ueta, M., Inatomi, T., Yokoi, N., Kaido, M., Dogru, M., Shimazaki, J., Tsubota, K., Yamada, M., Kinoshita, S., 2007. New grading system for the evaluation of chronic ocular manifestations in patients with Stevens-Johnson syndrome. *Ophthalmology*, 114(7), 1294–1302. <https://doi.org/10.1016/j.ophtha.2006.10.029>