

Histological Detection of Unauthorized Herbal and Animal Contents in Some Meat Products

Fahim A.E. Shaltout^{1*}, Mona N. Hussein^{2*}, Nada Kh. Elsayed¹

¹Department of Food Hygiene and Control (Meat hygiene), Faculty of Veterinary Medicine, Benha University, Benha 13736, Egypt.

²Department of Histology and Cytology, Faculty of Veterinary Medicine, Benha University, Benha 13736, Egypt.

*Correspondence

Fahim A.E. Shaltout

E-mail address: fahim.shaltout@fvvm.bu.edu.eg

Mona N. Hussein

E-mail address: mona.hussein@fvvm.bu.edu.eg

Abstract

The quality assurance of meat products is very important for human health protection. In this study, 50 samples from burger, kofta, and sausage were examined histologically for the detection of adulteration. Histological sections from the three meat products were stained with hematoxylin and eosin stain. Adulteration by unauthorized plant and animal tissues was detected microscopically. The results revealed that burger was adulterated with lung, heart, connective tissue, smooth muscles, cartilage, and plant tissues. Burger samples showed parasitic infection with sarcocystis within skeletal muscles. Kofta was adulterated with lung, connective tissue, smooth muscles, cartilage, blood vessels, and plant tissues. Sausage was adulterated with intestine, connective tissue, smooth muscles, cartilage, blood vessels, fat, and plant tissue. This study confirms the availability of histological examination in detecting adulteration of meat products and parasitic infection.

KEYWORDS

Adulteration, Burger, Kofta, Sausage, Sarcocyst.

INTRODUCTION

The meat industry became distributed worldwide. Meat product consumption has increased due to modern manufacturing techniques which provide good taste and low prices for consumers (Maghami *et al.*, 2022). Confirmation of meat products' compatibility with general hygienic standards is very necessary for human health preservation (Trienekens and Zuurbier, 2008). Adulteration of meat products increased to reduce their prices more than the original meat. Therefore, adulteration of these meat products was confirmed by several methods. Meat product adulteration could be detected by DNA analysis (Kang and Tanaka, 2018; Cottenet *et al.*, 2020). protein analysis for the detection of less valuable additives such as blood, connective tissue, and plasma (Jiang *et al.*, 2018). Small molecules metabolites analysis could be used for differentiation between different meat species (Lim *et al.*, 2017). DNA, protein, and small molecules metabolites analysis methods are time-consuming and invasive (Wang *et al.*, 2018). Therefore, researchers developed non-destructive technologies via spectroscopic analysis for detecting adulteration (Rady and Adedeji, 2018; Shaltout *et al.*, 2020b).

Histological examination was confirmed to be suitable for the detection of adulteration of meat products (Abd-Elhafeez *et al.*, 2022). Histology is an accurate technique in detecting adulteration by using frozen-thawed smoked salmon instead of fresh salmon industry (Pezzolato *et al.*, 2020). As well as, unauthorized tissue could be detected microscopically such as the lung, heart, intestine, ligaments, blood vessels, connective tissue, and plant tissue (Mokhtar *et al.*, 2018; Abdel-Maguid *et al.*, 2019). There-

fore, histology is an accurate rapid, and cheap method for the detection of adulteration in the food industry. The present study aimed to detect the adulteration of three meat products (burger, kofta, and sausage) via histological methods.

MATERIALS AND METHODS

Sampling

This study is performed on kofta, beef burgers, and oriental sausage. The three meat products were collected from a commercial hypermarket of the same brand name. The meat products were obtained from a local market (Giza, Egypt). The experiments were performed on fifty meat products.

Histological examination

Three random samples were collected from each meat product and preserved in 10% neutral buffered formalin for one week. Then the samples were dehydrated, cleared, and embedded in paraffin wax. Serial sections 5µm each were cut via a microtome for further hematoxylin and eosin staining. The photos were captured via Leica light microscope. The histological procedures were according to Bancroft and Gamble (2008).

Ethical approval

This study doesn't include the participation of humans or animals in the experiment performed by the authors.

RESULTS

The present study demonstrated the availability of microscopical examination for the detection of adulteration of meat products by unauthorized tissue. In general, the amount of skeletal muscles in the three meat products was lower than the amount of unauthorized tissue (Fig. 1). The skeletal muscle fibers are characterized by striated muscle fibers with a peripheral elongated nucleus in longitudinal sections. Adulteration by the addition of lung, plant tissue, cartilage, and fat were observed in the burger, kofta, and sausage samples (Fig. 1A-C).

In burger, several unauthorized tissues were noticed in sections observed by light microscope (Fig. 2). Cardiac muscles (heart) were noticed with their characteristic striated and branched muscle fibers (Fig. 2A). Connective tissues (collagenous fibers) were observed (Fig. 2B). Smooth muscles of the internal organs were detected in burger samples (Fig. 2C). *Sarcocystis* parasitic infection was found in cross sections of skeletal muscles (Fig. 2D). Several sections showed different kinds of plant tissue

including palisade and extrudate of soya, dicot leaf, and other kinds (Figs. 2E-I).

In kofta, dense regular bundles of collagen fibers were observed (Figs. 3A, and B). Smooth muscles of the internal organs were observed (Fig. 3C). Lung tissue was added to kofta samples (figure not shown). Several blood vessels were noticed in kofta sections (Fig. 3D). Hyaline cartilage (Fig. 3E) and three parts of the soya plant (palisade, extrudate, and cotyledon cells) were noticed (Figs. 3E and F). Other kinds of plant tissues were added to the kofta samples including onion (Figs. 3G, H, and I).

In sausage, intestinal villi were detected (Fig. 4A). Smooth muscles (Fig. 4B), connective tissue, blood vessels, and fat were also noticed. Several kinds of plant tissues including soya with food additives were added to sausage (Figs. 4C-I)

DISCUSSION

The obtained results indicated the addition of several unauthorized tissues in meat products. Recently food fraud increased

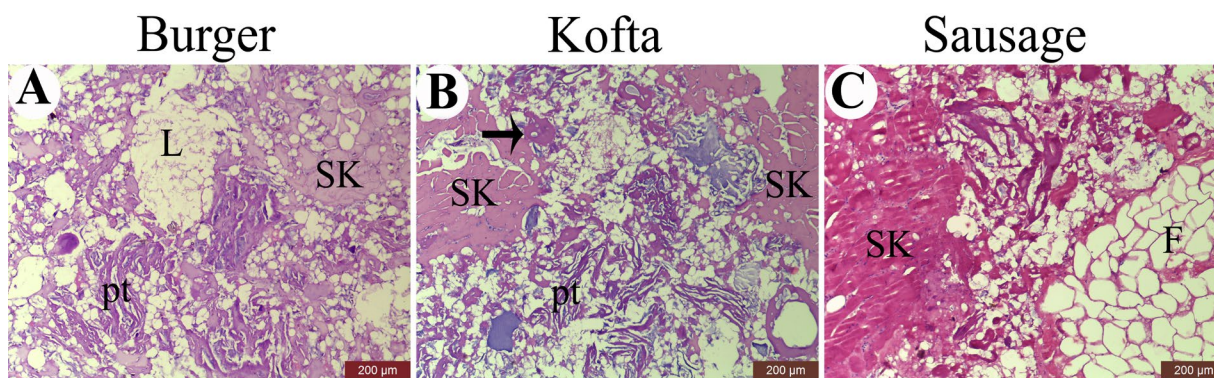


Fig. 1. Photomicrograph shows H&E staining of burger, kofta, and sausage. The figure shows cross sections of skeletal muscles (SK) and tissue adulteration by unauthorized tissue including lung tissue (L), plant tissue (pt), hyaline cartilage (arrow), and fat tissue (F).

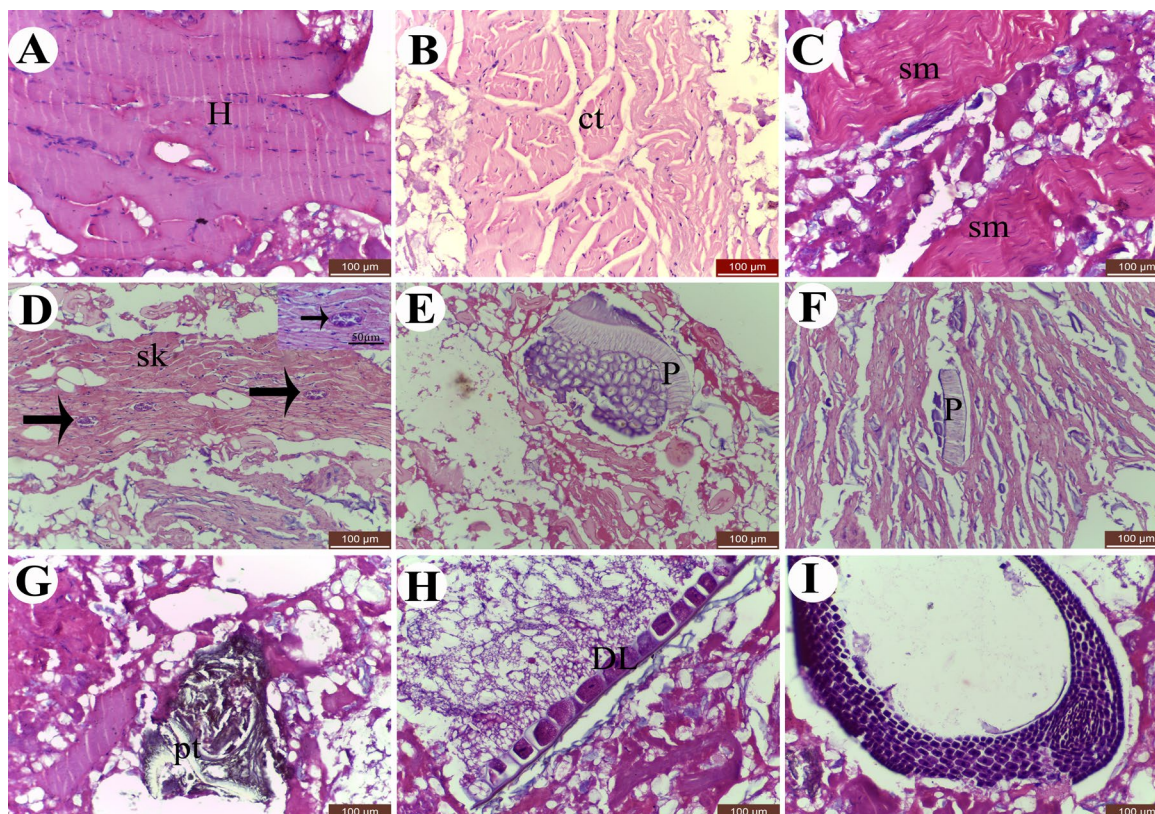


Fig. 2. Photomicrograph shows H&E staining of burger samples for detection of tissue adulteration with unauthorized tissue. (A) photomicrograph of cardiac muscle (H). (B) photomicrograph of connective tissue (ct). (C) photomicrograph of smooth muscle (sm). (D) photomicrograph of sarcocystis (arrows) within skeletal muscles (SK). (E) photomicrograph of palisade tissue of soya (p). (F) photomicrograph of palisade tissue (p) in between extrudate of soya. (G) photomicrograph of plant tissue (pt). (H) photomicrograph of Dicot leaf (DL). (I) photomicrograph of plant tissue.

via the use of unauthorized tissue to increase meat industry profitability (Ruiz Orduna *et al.*, 2015; Li *et al.*, 2020). Several governments established food safety strategies to protect consumers from food fraud (Charlebois *et al.*, 2016; Sammut *et al.*, 2021). Histology has proved to have a valuable role in the detection of meat product adulteration. Our results indicated adulteration

by unauthorized tissues including lung, heart, smooth muscles, bundles of connective tissue, hyaline cartilage, intestine, fat, and plant tissues. Following our results, Mokhtar *et al.* (2018) showed adulteration of minced meat and sausage by the addition of the heart, intestine, lung, fascia, thyroid gland, bone, cartilage, and plants. Additionally, Abdel-Maguid *et al.* (2019) illustrated

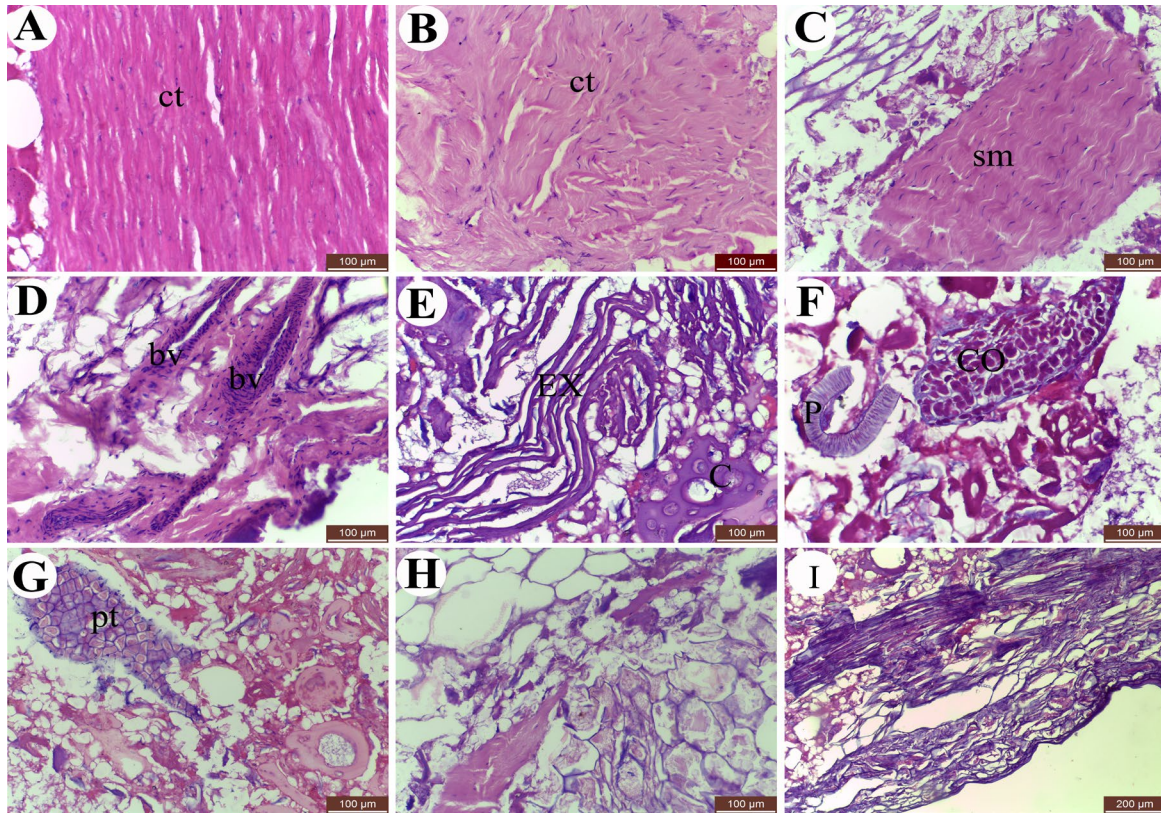


Fig. 3. Photomicrograph shows H&E staining of kofta samples for detection of tissue adulteration with unauthorized tissue. (A) and (B) photomicrographs of connective tissue (ct). (C) photomicrograph of smooth muscle (sm). (D) photomicrograph of blood vessels (bv). (E) photomicrograph of extrudate of soya (EX) and hyaline cartilage (C). (F) photomicrograph of palisade tissue (p) and cotyledon cells (CO) of soya. (G) plant tissue (pt), (H) epidermal cells of onion peel, and (I) photomicrograph of an onion root.

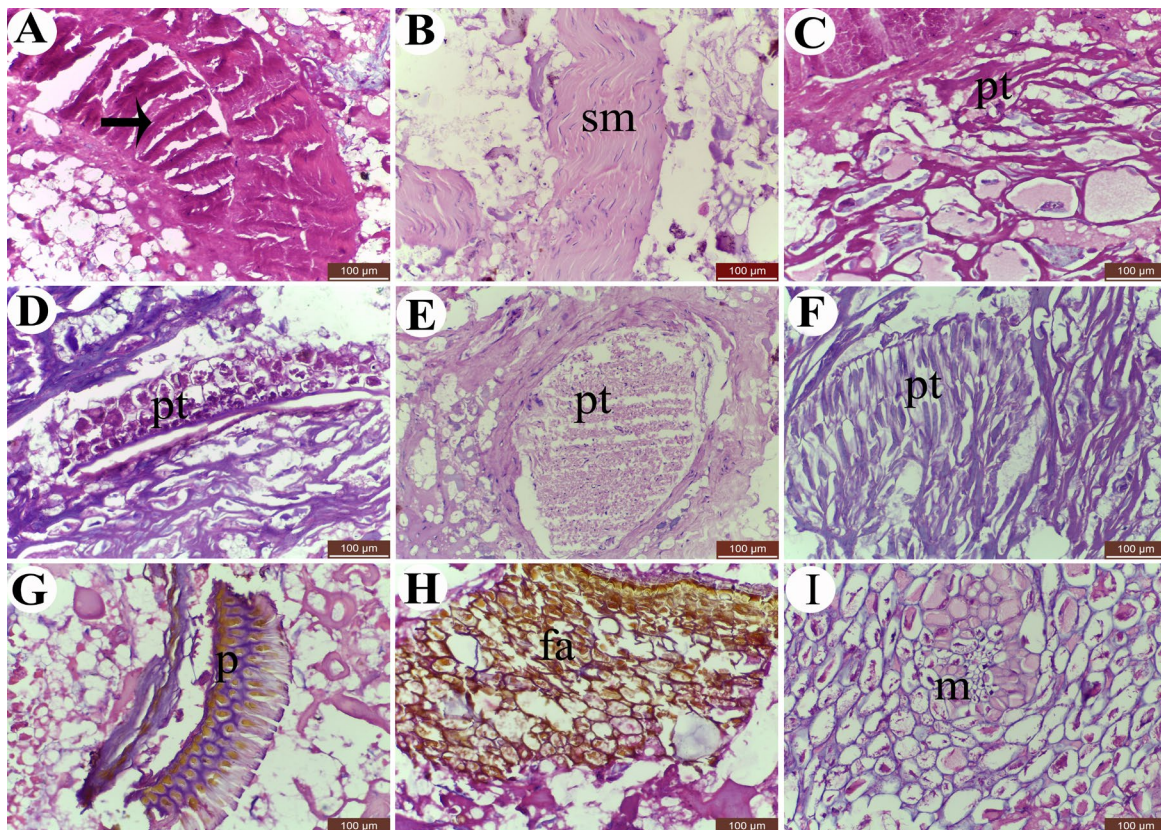


Fig. 4. Photomicrograph shows H&E staining of sausage samples for detection of tissue adulteration with unauthorized tissue. (A) photomicrograph of intestinal villi (arrow). (B) photomicrograph of smooth muscle (sm). (C) plant tissue (pt), (D) cucumber seeds, (E), and (F) show plant tissue (pt) within sausage samples. (G) photomicrograph of palisade tissue of soya (p). (H) photomicrograph of plant tissue with food additives (fa) has a brown color. (I) photomicrograph of plant leaf containing mesophyll (m).

adulteration with the nuchal ligament, lung, heart, tendons, fat, smooth muscles, cartilage, and blood vessels.

Both histological and ATPase enzyme activity were used for the detection of adulteration in different meat sandwiches (hawawshi, kofta, and shawerma) in New Valley City, Egypt. Several tissue types were detected histologically including lung, blood vessels, cartilage, spongy bone, adipose tissue, heart muscles, lymphatic tissue, and plant materials. ATPase enzyme activity detected the presence of dark (slow contracting) fetal tissue in comparison to light (fast contracting) adult muscle fibers (Abdel Hafeez *et al.*, 2016). Chicken gizzard and soya were detected via histological examination of minced beef meat. Therefore, histology is an effective technique for the detection of adulteration in minced meat (Sadeghinezhad *et al.*, 2016).

Ready to eat kofta and hawawshi sandwiches were found to be adulterated by chicken meat and other foreign tissues in Assiut city, Egypt (El-Aziz, 2018). As well as adulteration by the addition of heart muscles, smooth muscles of hollow organs, cartilage, bone, lung tissue, thyroid gland, intestinal tissue, proventriculus, tendons, ruminant stomach, brain, and nerve trunk. Furthermore, plant tissue was used including poppy seeds, cysts, and parts of parasites. This adulteration was confirmed histologically in meat products randomly collected from supermarkets in Assiut city, Egypt (Mokhtar *et al.*, 2018). In Iran sausage, minced meat, and hamburger were adulterated by the addition of smooth muscles, gizzard, glandular tissue, nerves, adipose tissue, skin, cartilage, bone, tendons, and plant tissue (Maghami *et al.*, 2022). Adulteration of low and high-priced meat products was confirmed following histological examination by light, scanning electron microscope (SEM), and fluorescence microscope in Sohag City, Egypt. Several tissues were used for meat products adulteration including cardiac muscles, cartilages, bone, and ligaments, tendons, and arteries. As well as, bacterial contamination was recognized (Abd-Elhafeez *et al.*, 2022).

For confirming the suitability of meat products for human consumption they should be evaluated for microbial, fungal (Hassanien *et al.*, 2018; Shaltout *et al.*, 2020a) and parasitic contamination. This study confirmed sarcocyst infection of skeletal muscles in beef burger. Consumption of infected meat products could affect human health and lead to the spread of pathogens (Mavi *et al.*, 2020). *Sarcocystis hominis* infect beef muscles and is pathogenic to the human when consumed via cyst-laden in undercooked meat (Pritt *et al.*, 2008).

CONCLUSION

This study proves the presence of food fraud by unauthorized tissue in burger, kofta, and sausage. Cardiac muscles, smooth muscles, lung tissue, connective tissue, blood vessels, hyaline cartilage, fat, and several kinds of plant tissue especially soya were detected in meat products. As well as parasitic infection by *sarcocystis* was observed in burger samples. Hematoxylin and eosin histological staining is a cheap, rapid, and valuable method for the detection of food fraud.

CONFLICT OF INTEREST

The authors declare that there is no conflict of interest.

REFERENCES

- Abd-Elhafeez, H.H., El-Sayed, A.M., Ahmed, A. M., Soliman, S.A., 2022. Detection of food fraud of meat products from the different brands by application of histological methods. *Microscopy Research and Technique* 85, 1538-1556.
- Abdel-Maguid, D.S., Zaki, R.S., Soliman, S.A., Abd-Elhafeez, H.H., Mohamed, S.A., 2019. Fraudulence risk strategic assessment of processed meat products. *Journal of Advanced Veterinary Research* 9, 81-90.
- Abdel Hafeez, H., Zaki, R., Abd El-Mageed, D., 2016. Applying light, histochemical and scanning histological methods for the detection of unauthorized animal and herbal content in street meat sandwich: what is in the sandwich we eat. *J Food Process Technol.* 7, 1-11.
- Bancroft, J. D., Gamble, M., 2008. Theory and practice of histological techniques. Elsevier Health Sciences.
- Charlebois, S., Schwab, A., Henn, R., Huck, C.W., 2016. Food fraud: An exploratory study for measuring consumer perception towards mislabeled food products and influence on self-authentication intentions. *Trends in Food Science & Technology* 50, 211-218.
- Cottenet, G., Blancpain, C., Chuah, P.F., Cavin, C., 2020. Evaluation and application of a next generation sequencing approach for meat species identification. *Food Control.* 110, 107003.
- El-Aziz, A., 2018. Molecular and histological investigation of adulterated ready-to-eat heated meat products with chicken substances. *International Food Research Journal* 25, 1948-1952
- Hassanien, E., Fahim, S., Mohammed, H., 2018. Quality assurance of some meat products. *J Dairy Vet. Anim. Res.* 7, 171-174.
- Jiang, X., Fuller, D., Hsieh, Y.H. P., Rao, Q., 2018. Monoclonal antibody-based ELISA for the quantification of porcine hemoglobin in meat products. *Food Chemistry* 250, 170-179.
- Kang, T. S., Tanaka, T., 2018. Comparison of quantitative methods based on SYBR Green real-time qPCR to estimate pork meat adulteration in processed beef products. *Food Chemistry* 269, 549-558.
- Li, Y.C., Liu, S.Y., Meng, F.B., Liu, D.Y., Zhang, Y., Wang, W., Zhang, J.M., 2020. Comparative review and the recent progress in detection technologies of meat product adulteration. *Comprehensive Reviews in Food Science and Food Safety* 19, 2256-2296.
- Lim, D.K., Long, N.P., Mo, C., Dong, Z., Cui, L., Kim, G., Kwon, S.W., 2017. Combination of mass spectrometry-based targeted lipidomics and supervised machine learning algorithms in detecting adulterated admixtures of white rice. *Food Research International* 100, 814-821.
- Maghami, N. D., Nabipour, A., Mohsenzadeh, M., Torabi, M., 2022. Histological and stereological approaches for detection of tissues and fraud in some meat products. In: *Veterinary Research Forum* 13, 47-53.
- Mavi, S.A., Teimouri, A., Mohebbali, M., Yazdi, M.K.S., Shojaaee, S., Rezaian, M., Salimi, M., Keshavarz, H., 2020. Sarcocystis infection in beef and industrial raw beef burgers from butcheries and retail stores: A molecular microscopic study. *Heliyon* 6, e04171.
- Mokhtar, D.M., Abd-Elaziz, D.M., Youssef, H., Taha, A., 2018. Applied histological and chemical analysis for detection of adulteration of minced meat and sausage. *Journal of Advanced Microscopy Research* 13, 345-353.
- Pezzolato, M., Baioni, E., Maurella, C., Varello, K., Mestro, S., Balsano, A., Bozzetta, E., 2020. Distinguishing between fresh and frozen-thawed smoked salmon: Histology to detect food adulteration in high-value products. *Journal of Food Protection* 83, 52-53.
- Pritt, B., Trainer, T., Simmons-Arnold, L., Evans, M., Dunams, D., Rosenthal, B.M., 2008. Detection of *Sarcocystis* parasites in retail beef: a regional survey combining histological and genetic detection methods. *Journal of Food Protection* 71, 2144-2147.
- Rady, A., Adedeji, A., 2018. Assessing different processed meats for adulterants using visible-near-infrared spectroscopy. *Meat Science* 136, 59-67.
- Ruiz Orduna, A., Husby, E., Yang, C.T., Ghosh, D., Beaudry, F., 2015. Assessment of meat authenticity using bioinformatics, targeted peptide biomarkers and high-resolution mass spectrometry. *Food Additives and Contaminants: Part A.* 32, 1709-1717.
- Sadeghinezhad, J., Hajimohammadi, B., Izadi, F., Yarmahmoudi, F., Latorre, R., 2016. Evaluation of the morphologic method for the detection of animal and herbal content in minced meat. *Czech Journal of Food Sciences* 33, 564-569.
- Sammur, J., Gopi, K., Saintilan, N., Mazumder, D., 2021. Facing the challenges of food fraud in the global food system *Food Authentication and Traceability.* Elsevier. pp. 35-63.
- Shaltout, F., Lamda, H., Edris, E., 2020a. Bacteriological examination of cooked meat and chicken meals. *Cohesive Journal of MMicrobiology Infectious Disease* 3, 1-5.
- Shaltout, F. A., El Shater, M.A., Haza, W.M., 2020b. Prevalence of Some Chemical Hazards in Some Meat Products. *Concepts of Dairy and Veterinary Sciences* 3, 313-317.
- Trienekens, J., Zuurbier, P., 2008. Quality and safety standards in the food industry, developments and challenges. *International Journal of Production Economics* 113, 107-122.
- Wang, W., Peng, Y., Sun, H., Zheng, X., Wei, W., 2018. Spectral detection techniques for non-destructively monitoring the quality, safety, and classification of fresh red meat. *Food Analytical Methods* 11, 2707-2730.