

Pathological and Clinical Pathological Studies on Some Immune Stimulant Drugs in Albino Rats

Moustafa S. Abou El-Fetouh¹, Nora M. Elseddawy¹, Hagar M. Abdelsamia^{2*}

¹Department of Pathology, Faculty of Veterinary Medicine, Zagazig University, Zagazig, Egypt.

²Bachelor of Veterinary Medical Sciences, Faculty of Veterinary Medicine, Zagazig University, Zagazig, Egypt.

*Correspondence

Corresponding author: Hagar M. Abdelsamia
E-mail address: hagersakr814@gmail.com

Abstract

A natural fermentation product called ivermectin (IVM), which is generated from the soil bacterium *Streptomyces avermitilis*, is a broad range of anthelmintic, pesticide, and antiviral. Several immune system functions are impacted by zinc. The goal of the current investigation was to determine how therapeutic doses of ivermectin and monozinc affected the liver, spleen, and lung in terms of histopathological changes, as well as the clinical results of lymphocytes, TNF, and γ globulin. Fifteen female white albino rats were equally divided into three groups, group 1 was assigned as a control, and group 2 received a therapeutic dose of ivermectin (0.2 mg/kg BW/SC) with 0.18 mg of zinc per day orally for one month, and group 3 that received a double therapeutic dose of zinc (0.36 mg/kg BW/SC) orally for one month. The observed macroscopic histopathological changes in group 2 were enlargement of the livers with microscopical mild vacuolation of some hepatocytes with hyperplasia of Kupffer cells. Some areas of the liver showed necrotic changes. The lungs were congested and showed catarrhal pneumonia. The spleens were enlarged and congested, and showed microscopically, hyalinization of the central arterioles with an increase in the lymphocytes of the white pulp and hemorrhage in the red pulp. The histopathological changes in group 3 indicated congestion of the central vein and hepatic sinusoids with hemosiderin pigment and perivascular aggregation of mononuclear cells in the liver, while the lungs, microscopically showed mild catarrhal bronchitis, and the spleen showed hyperplasia of the lymphoid follicle of the white pulp and reduction of the red pulp. The obtained results of the present study indicated that ivermectin with zinc act as immunostimulants for different cells responsible for immunity in the body tissue.

KEYWORDS

Ivermectin, Zinc, Liver, Spleen, Therapeutic dose

INTRODUCTION

During the recent outbreak of COVID-19, various drugs were used in the protocol of the treatment, we here are focusing on ivermectin and zinc.

Any disease or condition brought on by a virus is referred to as a viral disease. Viral illnesses are not always contagious. They thus don't always spread from one person to another. The flu, the common cold, HIV, and herpes are examples of communicable viral infections. The bite of an infected insect is one method through which some viral illnesses spread (Ashour *et al.*, 2019). New broad-spectrum antiviral medications have been emphasized in recent years as a way to protect against a variety of viruses while lowering the costs and resistance risks of producing drugs that are unique to each virus (Caly *et al.*, 2020).

The need for developing efficient treatments against the SARS-CoV-2 causal agent as well as other pathogenic coronaviruses (CoV) that have previously surfaced or may do so in the future has come to light as a result of the coronavirus disease 2019 (COVID-19) pandemic. Therefore, scientists are concentrating on CoV replication cycle phases that may be susceptible to suppression by general or particular antiviral drugs (Adegboro

et al., 2021).

In recent years, researchers have demonstrated the broad-spectrum anti-parasitic drug ivermectin's efficacy against a variety of viruses (Elalfy *et al.*, 2021). Ivermectin works by preventing the host importin alpha/beta-1 nuclear transport proteins from doing their function. These proteins are crucial components of an intracellular transport system that viruses employ to increase infection by stifling the host's defense mechanism. Additionally, ivermectin docking may prevent the severe acute respiratory syndrome coronavirus 2 (SARS-CoV-2) spike protein from adhering to the membrane of human cells (Boretti, 2022).

Zinc is thought to be necessary for DNA and protein synthesis as well as cell division. Zinc is also essential for bone mineralization, healthy thyroid function, blood coagulation, cognitive abilities, sperm generation, taste acuity, connective tissue growth and maintenance, immune system function, prostaglandin formation, tissue growth, and other processes. To keep the level of serum testosterone normal, zinc is required. The vesicles of the mossy fiber system of the brain's hippocampus contain zinc (Burton, 2005). To maintain good health with a better cell-mediated immune response, taking zinc supplements is recommended. Skin health depends on the nutrient zinc. Brain regions that re-

ceive and process information from taste and smell receptors are activated by zinc. Levels of zinc in the plasma have been demonstrated to affect hunger and taste preferences (Bonaventura *et al.*, 2015). Growth retardation, low blood pressure, weakened bones, loss of taste and smell, appetite loss, weight loss, pale skin, diarrhea, hair loss, exhaustion, and white spots beneath the fingernails are just a few of the signs of zinc deficiency. The lack of zinc has been linked to immunological dysfunction and increased vulnerability to infection in older people (Cheng *et al.*, 2018). The generation of immune system cells in the body, which guards against illness and infection, is tightly controlled by zinc. Immunity often declines as we age. It has been demonstrated that giving older adults enough zinc and a nutritious diet can reduce their risk of contracting infectious diseases (Tuerk and Fazel, 2009).

This study aimed to investigate the histopathological effects of either ivermectin or zinc on the liver, spleen, and lungs of albino rats.

MATERIALS AND METHODS

Experimental animals

All experiments were conducted according to Zagazig University guidelines for the use of laboratory animals. Following the laboratory standards, 15 mature albino rats weighing between 150 and 200 g were kept at 25 ± 2 °C with a 55–64 % relative humidity and a 12 h light–dark cycle, at the laboratory animal facility, Faculty of Veterinary Medicine, Zagazig University, Egypt. They have unlimited access to regular pellet feed as well as water. Throughout the entire experiment, rats were housed in the same sanitary and environmental circumstances.

Experiment design

In the study, 15 female white albino rats, purchased from the laboratory animal facility at Faculty of Veterinary Medicine, Zagazig University, Egypt, were divided equally into three groups: control group (G1), group 2 (G2) received a therapeutic dose of ivermectin (0.2 mg/kg BW/SC) along with 0.18 mg of zinc every day orally for a month, and group 3 (G3) received a double therapeutic dose of zinc (0.36 mg/kg BW) orally for a month.

Blood samples

All groups' blood samples were taken from the Middle Canthus of the eye. Blood was drawn with anticoagulant for complete blood count according to Lewis *et al.* (2006), and without anticoagulant for estimation of TNF-alpha using rat TNF-alpha ELISA kit (ThermoFisher Scientific, Austria), and gamma-globulin according to Bianchi *et al.* (1995).

Histopathological studies

After every rat sacrifice, samples were obtained from the spleen, liver, and lung. In a 10% buffered neutral formalin solution, these samples were fixed. Following the correct fixation, the samples were dehydrated in ethyl alcohol at ascending concentrations (50–100%), cleaned in xylol, embedded in paraffin, and finely blocked. Hematoxylin and eosin (H&E) staining was used to section the samples into 5 m thick sections for microscopic analysis (Suvarna *et al.*, 2019). Autoclaved scissors and disposable forceps were utilized for sampling during the necropsy investigation.

Statistical analysis

Analysis of variance (ANOVA) was used in the statistical analysis. At a significant threshold of 0.05, Duncan's Multiple Range was employed to determine differences in treatment means. The SPSS program was used to run all of the statistics on the computer.

RESULTS

Hematological and biochemical analysis

Groups 2 and 3 had the highest blood lymphocytes count (804.80 ± 57.51), and (1036.40 ± 52.81), respectively, while G1 had the lowest lymphocytes count (269.33 ± 29.67). However, G2 had the highest tumor necrosis factor-alpha (210.60 ± 27.05), followed by G1 (86.00 ± 7.00), and G3 (53.66 ± 6.34). Gamma-globulin revealed that there was a slight statistical significance among the examined groups (Table 1).

Table 1. Effects of ivermectin and zinc on the investigated parameters.

	Lymphocytes (μ l)	TNF α (pg/ml)	γ -globulin (g/dl)
Group 1 (n.=5)	269.33 ± 29.67^c	86.00 ± 7.00^b	0.82 ± 0.04^b
Group 2 (n.=5)	804.80 ± 57.51^b	210.60 ± 27.05^a	1.26 ± 0.04^a
Group 3 (n.=5)	1036.40 ± 52.81^a	53.77 ± 6.34^c	1.17 ± 0.05^a

Data are presented as Mean \pm SE. Values within the same column carrying different superscript letter are significantly different at $p < 0.05$.

Histopathological findings

Various histopathological changes were demonstrated in the liver, lung, and spleen of the treatment groups.

Group 2

Liver

Macroscopically, the liver was enlarged, microscopically the liver showed mild vacuolation of some hepatocytes with hyperplasia of Kupffer cells (Fig. 1a). In some cases, the hepatocytes showed fatty change with the nucleus in the peripheral giving signet ring appearances (Fig. 1b), the portal area showing congestion of portal vein with mild hyalinization in its wall (arrow), and chronic cholangitis (Fig. 1c).

Lungs

Macroscopically, the lung was congested, microscopically, the lung showed catarrhal pneumonia represented by hyperplasia of lining epithelium of bronchi and few desquamated epithelial with peribronchial leukocytic infiltrations (Fig 1d). In addition, thickening in the interalveolar septa by mononuclear cell infiltration and atelectasis of some alveoli were observed, and others showed emphysema (Fig. 1e). Perivascular aggregation of mononuclear cells was also seen (Fig. 1f).

Spleen

Macroscopically, the spleen was enlarged and congested, microscopically, the spleen showed hyalinization of central arterioles (Fig. 1g) showing hyperplasia of the lymphoid follicle of white pulp (Fig. 1h).

Rats treated with a double therapeutic dose of zinc (Group 3)

Spleen

Liver

Macroscopically, liver was congested, microscopically, showed congestion of the central vein and hepatic sinusoids with hemosiderin pigment (Fig. 2a), and perivascular aggregation of mononuclear cells was also seen (Fig. 2b). The portal area showed thickening in the wall of the portal vein and the bile duct showed mild cholangitis represented by thickening in the wall of the bile duct by fibrosis and mononuclear cell infiltration (Fig. 2c).

Lungs

Macroscopically, the lungs were congested, and microscopically showed mild catarrhal bronchitis, and thickening and hyalinization in the wall of the blood vessel with aggregation of lymphocytes peri bronchial forming lymphoid follicles (Fig 2d).

Macroscopically, spleen was enlarged, and microscopically showed hyperplasia of the lymphoid follicle of white pulp and reduction of the red pulp (Fig. 2e).

DISCUSSION

Ivermectin, an antiviral medicine, and zinc, an immunostimulant treatment, were among the standard preventive measures used during the Covid-19 outbreak. Through an examination of the histological and clinicopathological alterations in the tissue and the blood, this work demonstrated the negative effects of ivermectin and zinc on the albino rats' tissue. Group (2) demonstrated nasal discharges, anorexia, and depression. These symptoms could be caused by intestinal edema or epithelial cell necrosis brought on by high ivermectin doses (Ashraf *et al.*, 2021). Topp *et al.* (2015) reported that zinc is a vital trace element for all forms of life, and our clinical symptoms supported their findings.

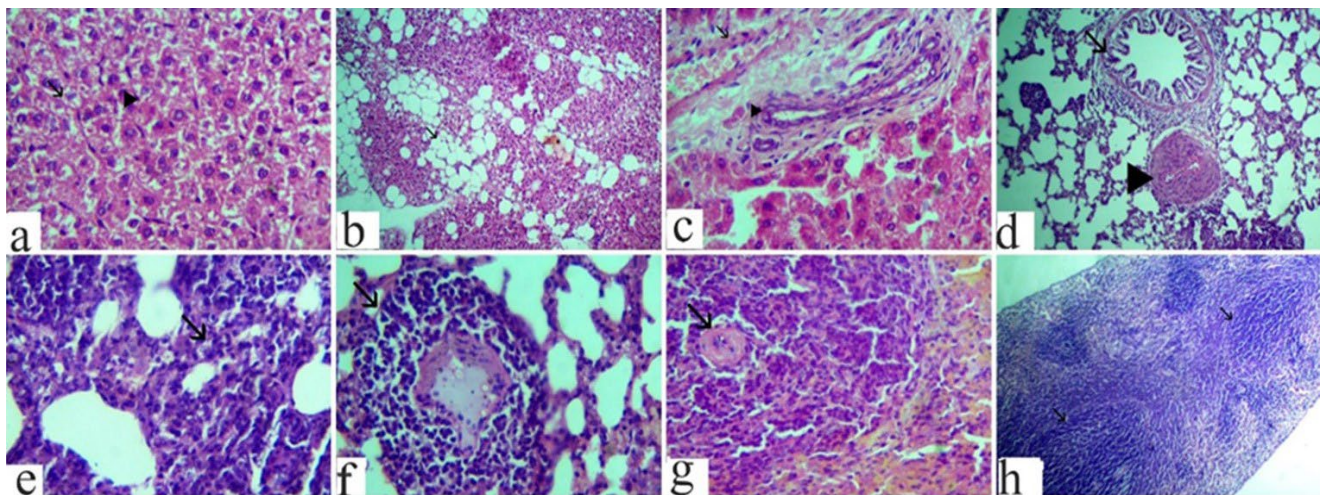


Fig. 1. Photomicrograph of H&E stained tissue group (2), liver a-c: a: mild vacuolation (arrow) and hyperplasia of Kupffer cells (arrowhead), x1200, b: fatty (arrow), x300, c: the portal area showing congestion of portal vein with mild hyalinization in its wall (arrow) and chronic cholangitis (arrowhead), x1200. d-f (lung), d: catarrhal bronchitis (arrow) thickening and hyalinization in the wall of peribronchial blood vessels (arrowhead), x300. e: thickening in the interalveolar septa by mononuclear cell infiltration (arrow), x1200. f: perivascular aggregation of mononuclear cells (arrow), x1200. g-h (spleen), g: hyalinization of central arterioles in the white pulp (arrow), x1200. h: multiple hyperplasias in the white pulps with a reduction in the size of red pulps (arrow)x300.

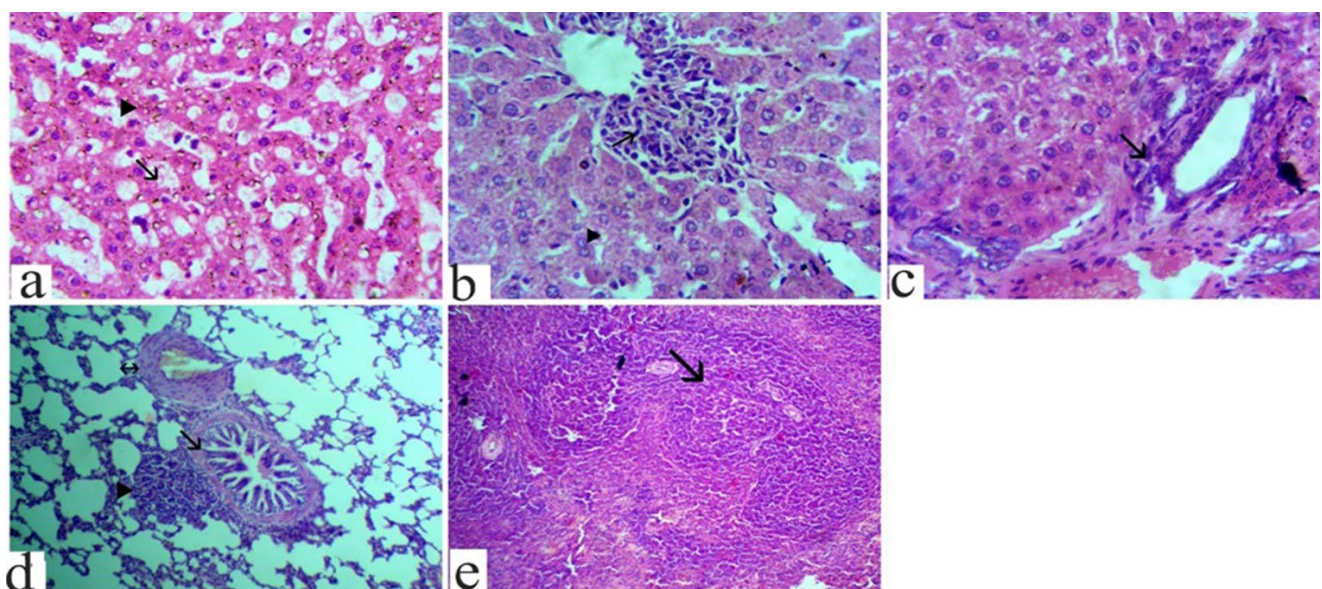


Fig. 2. Photomicrograph of H&E-stained tissue group (3), liver a-c: a: dilation of hepatic sinusoids (arrow) with the presence of brown pigment of hemosiderin (arrowhead), x1200. b: perivascular aggregation of mononuclear cells (arrow) with hemosiderin pigment (arrowhead), x1200. c: the portal area of the liver showing mild cholangitis (arrow), x1200. D: (lung), mild catarrhal bronchitis (arrow), and thickening and hyalinization in the wall of the blood vessel (arrow with 2head) with aggregation of lymphocytes peri bronchial forming lymphoid follicles (arrowhead), x1200. e: (spleen), hyperplasia of the lymphoid follicle of white pulp (arrow), x300

It was acknowledged that zinc was important for human nutrition and general health. Zinc is most likely involved in cell signaling and has been linked to changes in hormone release and nerve impulse transmission, according to Webster *et al.* (2001).

The obtained findings revealed a very high platelet count and a very slight increase in lymphocytic count (79.8%). Both TNF- α and gamma-globulin levels were elevated. Findings from this study concur with those of McClain and Su (1983). Likely, Qureshi *et al.* (1996) and Ali *et al.* (1988), noted that the adverse effects of ivermectin include lowering platelets, while zinc supplementation has been demonstrated to increase the cell-mediated immune response of healthy aged individuals.

In the present study, macroscopically the spleen was larger and congested, and microscopic examination revealed white pulp lymphoid follicle hyperplasia. These findings are related to zinc's effects on the immune system in general. Neutrophils, NK cells, and other cells mediating innate immunity all require zinc for appropriate growth and operation. Zinc deficiency also affects macrophages. Zinc deficiency has an impact on phagocytosis, intracellular killing, and cytokine generation. T and B cell development and function are negatively impacted by a zinc deficit (Qureshi *et al.*, 1996). The liver was enlarged under the microscope and revealed minor vacuolation of certain hepatocytes as well as Kupffer cell hyperplasia, these findings concur with Sherman (1992). They reported that zinc is crucial in controlling the body's immune system's cell synthesis, which guards against illness and infection. Besides, Ashraf *et al.* (2021), several ivermectin investigations have also revealed potential anti-inflammatory characteristics, which have been hypothesized to be helpful in COVID-19 patients.

In group (3), the most recent clinical symptoms were anorexia, nasal discharges, dizziness, flatulence, vomiting, and diarrhea, these symptoms are partially matched those of Suzuki *et al.* (2008), who demonstrated that zinc intake from drinking water needed to exceed 15 mg/L to cause nausea, vomiting, and diarrhea. Zinc salts simultaneously influence multiple organs, as demonstrated by zinc phosphide. Ingestion of this rodenticide causes the release of phosphine gas, which can enter the bloodstream and harm the lungs, liver, kidney, heart, and central nervous system. This gas is triggered by reactions with water and stomach acid. Stomach aches and diarrhea are indications of mild zinc phosphide poisoning. And we were somewhat in accord with Socha *et al.* (2021), who demonstrated that zinc salts have a propensity for being corrosive and that ingesting them can seriously harm the mouth, throat, and stomach. Initial symptoms may include vomiting and burning in the mouth and pharynx, as well as erosive pharyngitis, esophagitis, and gastritis. Gastrointestinal hemorrhage and acute pancreatitis are examples of complications.

Hematological and biochemical data from this study revealed a significant increase in lymphocytic count (101.56%) and a very high platelet count. Gamma-globulin levels were high on the opposite side, TNF- α levels were high, and total neutrophils were very low (13%). According to Vallee and Falchuk (1993), sideroblastic anemia, hypochromic microcytic anemia, leukopenia, lymphadenopathy, neutropenia, hypocupremia, and hypoferrinemia are the most frequent side effects of long-term, high zinc intakes (range from 150 mg/day to 1-2 g/day). After stopping the intake of zinc with or without copper supplementation, patients frequently return to normal blood patterns; reduced blood platelets have been documented.

In the current study, the liver was engorged on a macroscopic level. Microscopically, hemosiderin pigment and perivascular aggregation of mononuclear cells were seen in the hepatic sinusoids, and mild cholangitis was represented by thickening of the bile duct's wall by fibrosis and infiltration of mononuclear cells. The portal area also showed a thickening in the wall of the portal vein. The obtained results partially supported those of Wang and Zhou (2010), who demonstrated that elevated copper and zinc levels were associated with severe chronic cholestatic liver disease that progressed to end-stage biliary cirrhosis in a limited

number of Cree and Ojibwa-Cree children. Since there was no evidence that the children had been exposed to excessive zinc, it is possible that the consequences were brought on by an inherited malfunction in metal metabolism, other dietary or environmental factors, or genetic factors.

Spleen was enlarged macroscopically. Microscopically, white pulp lymphoid follicle hyperplasia and red pulp decrease were visible, these findings corroborated Nowak *et al.* (2015) findings that zinc has an impact on many immune system functions. Neutrophils, NK cells, and other cells mediating innate immunity all require zinc for appropriate growth and operation. Zinc deficiency also affects macrophages. Zinc deficiency has an impact on phagocytosis, intracellular killing, and cytokine generation. The development and operation of T and B cells are negatively impacted by zinc deficiency. Zinc's capacity to act as an antioxidant and stabilize membranes raises the possibility that it contributes to the protection of harm brought on by free radicals during inflammatory processes.

CONCLUSION

Ivermectin with zinc act as an immunostimulant for different cells responsible for immunity in the body tissue. Double doses of zinc induce mild lesions in the examined organs, especially the liver. We recommended that zinc with ivermectin must be used only at therapeutic doses.

CONFLICT OF INTEREST

The authors declare that they have no conflict of interest.

REFERENCES

- Adegboro, B., Lawani, O.A., Oriaifo, S. E., Abayomi, S.A., 2021. A review of the anti-viral effects of ivermectin. *Afr. J. Clin. Exper. Microbiol.* 22, 322-329.
- Akhtar, A., Deshmukh, A.A., Raut, C.G., Somkuwar, A.P., Bhagat, S.S., 2012. Prallethrin induced serum biochemical changes in Wistar rats. *Pestic. Biochem. Physiol.* 102, 160-168.
- Ali, A.A., Fahmy, M.F.M., Edres, N.M., 1988. Pathologic and clinicopathologic studies on antiparasitic drug ivermectin toxicosis in albino rats. *Zag. Vet. J.* 16, 19-31.
- Alvinerie, M., Sutra, J. F., Galtier, P., 1993. Ivermectin in goat plasma and milk after subcutaneous injection. *Vet. Res.* 24, 417-421.
- Arise, R.O., Malomo, S.O., Oyewole, O., 2012. Histopathological changes in selected tissues of ivermectin and /albendazole treated rats. *Inter. J. Toxicol. Appl. Pharma.* 2, 1-5.
- Ashour, D.S., 2019. Ivermectin: From theory to clinical application. *Inter. J. Antimicrob. Agents* 54, 134-142.
- Ashraf, S., Sohaib Ashraf, Iqra Farooq, Sidra Ashraf, Moneeb Ashraf, Muhammad Ahmad Imran, Larab Kalsoom, Rutaba Akmal, Muhammad Ghufan, Sundas Rafique, Muhammad Kiwan Akram, Zaigham Habib, Uzma Nasim Siddiqui, Ammara Ahmad, Shahroze Arshad, Muhammad Abdul Rehman Virk, Mehak Gul, Abeer Bin Awais, Muhammad Hassan, Syed Sami Hussain Sherazi Zartasha Safdar, Isra Munir, Hamna Khalid, Khalid Munir, Nighat Majeed, Yaser Masuod Alahmadi, Ayesha Humayun, Qazi Abdul Saboo, Ali Ahmad, Muhammad Ashraf, Izhar, M., 2021. Anti-COVID property of subcutaneous ivermectin in synergy with zinc among midlife moderately symptomatic patients: a structured summary of a study protocol for a randomized controlled trial. *Trials* 22, 591.
- Bianchi, A.T.J., Moonen-Leusen, H.W.M., van der Heijden, P.J., Bokhout, B.A., 1995. The use of a double antibody sandwich ELISA and monoclonal antibodies for the assessment of porcine IgM, IgG, and IgA concentrations. *J. Vet. Immunol. Immunopathol.* 44, 309-317.
- Bonaventura, P., Benedetti, G., Albarède, F., Miossec, P., 2015. Zinc and its role in immunity and inflammation. *Autoimmun. Rev.* 14, 277-285.
- Boretti, A., 2022. Zinc augments the antiviral potential of HCQ/CQ and ivermectin to reduce the risks of more serious outcomes from COVID-19 infection. *J. Trace Elem. Med. Biol.* 126954.
- Burton Jr, G.A., Nguyen, L.T., Janssen, C., Baudo, R., Mc William, R., Bossuyt, B., Green A., 2005. Field validation of sediment zinc toxicity. *Environ. Toxicol. Chem.* 24, 541-553.

- Caly, L., Druce, J.D., Catton, M.G., Jans, D.A., Wagstaff K.M., 2020. The FDA approved drug ivermectin inhibits the replication SARS-CoV-2 *in vitro*. *Antiviral Res.* 2020, 104787.
- Cheng, Z., Thomas, P.W., Ju L, Bergstrom, A., Mason, K, Clayton, D, Crowder, M.W., 2018. Evolution of New Delhi metallo- β -lactamase (NDM) in the clinic: effects of NDM mutations on stability, zinc affinity, and mono-zinc activity. *J. Biol. Chem.* 293, 12606-12618.
- Chen, T.A., O'Brien, R.A., Rieke, R.D., 1993. Use of highly reactive zinc leads to a new, facile synthesis for polyarylenes. *Macromolecules* 26, 3462-3463.
- Cousins, R.J., 1986. Toward a molecular understanding of zinc metabolism. *Clin. Physiol. Biochem.* 4, 20-30.
- Elalfy, H., Besheer, T., El-Mesery, A., El-Gilany, A.H., Soliman, M. A., Al-hawarey, A., El-Bendary, M., 2021. Effect of a combination of nitazoxanide, ribavirin, and ivermectin plus zinc supplement (MANS. NRIZ study) on the clearance of mild COVID-19. *J. Med. Virol.* 93, 3176-3183.
- Epstein, S.E., Hollingsworth, S.R., 2013. Ivermectin-induced blindness treated with intravenous lipid therapy in a dog. *J. Vet. Emerg. Crit. Care* 23, 58-62.
- Fosmire, G. J., 1990. Zinc toxicity. *Amer J. Clin. Nutr.* 51, 225-227.
- Frassinetti, S., Bronzetti, G.L., Caltavuturo, L., Cini, M., Della Croce, C., 2006. The role of zinc in life: a review. *J. Environ. Pathol. Toxicol. Oncol.* 25.
- Lewis, S.M., Bain, B.J., Bates, I., 2006. *Dacie and Lewis Practical Haematology*, 10th edn. The Netherlands: Elsevier.
- McClain, C.J., Su, L.C., 1983. Zinc deficiency in the alcoholic: a review. *Alcoholism: Clin. Exper. Res.* 7, 5-10.
- Mansour, S.A., Mossa, A.H., 2010. Oxidative damage biochemical and histopathological alterations in rats exposed to chlorpyrifos and the antioxidant role of zinc. *Pestic. Biochem. Phys.* 96, 14-23.
- Nowak, P., Troseid, M., Avershina, E., Barqasho, B., Neogi, U., Holm, K., Hov, J.R., Noyan, K., Vesterbacka, J., Svärd, J., Rudi, K., 2015. Gut microbiota diversity predicts immune status in HIV-1 infection. *Aids* 29, 2409-2418.
- Qureshi, S.A., Leung, S., Kerr, I.M., Stark, G.R., Darnell Jr, J.E., 1996. Function of Stat2 protein in transcriptional activation by alpha interferon. *Mol. Cell. Biol.* 16, 288-293.
- Roy, A.P., Charkraborty, A.K., Mandol, T.K., Ghosh, R.K., 1992. Effect of consecutive administration of ivermectin on hematological and certain enzyme activities of goat. *Indian. Vet. Med. J.* 16, 2.
- Sherman, A.R., 1992. Zinc, copper, and iron nutrition and immunity. *J. Nutr.* 122, 604-609.
- Socha, K., Klimiuk, K., Naliwajko, S.K., Soroczyńska, J., Puścion-Jakubik, A., Markiewicz-Żukowska, R., Kochanowicz, J., 2021. Dietary habits, selenium, copper, zinc and total antioxidant status in serum in relation to cognitive functions of patients with Alzheimer's disease. *Nutrients* 13, 287.
- Suvarna, K.S., Layton, C., Bancroft, J.D., 2019. *Bancroft's theory and practice of histological techniques*. 8th ed. London, UK: Elsevier Ltd., p. 672.
- Topp, C.W., Østergaard, S.D., Søndergaard, S., Bech, P., 2015. The WHO-5 Well-Being Index: a systematic review of the literature. *Psychother. Psychosom.* 84, 167-176.
- Trailovic, S.M., Varagie, V.M., 2007. The effect of ivermectin on convulsions in rats produced by Lidocaine and Strychnine. *Vet. Res. Commun.* 31, 863-72.
- Tuerk, M.J. and Fazel, N., 2009. Zinc deficiency. *Curr. Opin. Gastroenterol.* 25, 136-143.
- Vallee, B.L., Falchuk, K.H., 1993. The biochemical basis of zinc physiology. *Physiol. Rev.* 73, 79-118.
- Wang, X., Zhou, B., 2010. Dietary zinc absorption: A play of Zips and ZnTs in the gut. *IUBMB life* 62, 176-182.
- Webster, K.A., Prentice, H., Bishopric, N.H., 2001. Oxidation of zinc finger transcription factors: physiological consequences. *Antioxid. Redox Signal* 3, 535-548.