



---

**Delivery of Cyclopia Monster Fetus from a Crossbred Heifer Suffering  
from Dystocia**

Asloob Ahmad Malik, Gowher Gull Sheikh, Farooz Ahmad Lone, Rafiqul Islam, Arjuma Khatun

*Division of Animal Reproduction, Gynecology and Obstetrics, Faculty of Veterinary Sciences and Animal Husbandry,  
Sher-E-Kashmir University of Agricultural Sciences and Technology of Kashmir. Shuhama, Srinagar-190 006 India*

Accepted 10 October 2013

---

**Abstract**

A three-year-old crossbred heifer was presented at full term with a history of recurrent straining for the last 9 hours and ruptured water bags. A live fetus was delivered successfully. The calf had a dome shaped head, centrally located orbit with protruding tongue giving it a monkey face like appearance. The calf was unable to stand after its delivery due to ankylosed limbs. The fetus died 8 hours after its successful delivery.

*Keywords:* Cyclopia; Dystocia; Fetus; Heifer; Monster

---

**Introduction**

Cyclopia is a rare form of holoprosencephaly and a congenital disorder characterized by the failure of the embryonic prosencephalon to properly divide the orbits of the eye into two cavities. It is most commonly encountered in pig and sheep (Roberts, 1971) but rarely reported in caprine (Kantharaj, 2010) and bovine (Ozcan *et al.*, 2006; Honparkhe *et al.*, 2009). The present case report puts on a record of dystocia attributable to cyclopia monster calf and its successful pervaginal delivery through obstetrical maneuvers in a crossbred heifer.

**Case history and observations**

A three-year-old crossbred heifer was presented at full term with a history of recurrent straining for the last 9 hours and ruptured water bags. Upon careful examination, it was found that the clinical parameters like temperature, pulse and respiratory rate were within normal range. Pervaginal examination revealed a live fetus in anterior longitudinal presentation and dorsosacral position. Head of the

fetus was out of reach due to complete downward deviation towards the breast region (Breast head posture) and both the forelimbs flexed from the shoulder region.

**Treatment and Discussion**

The fetus was repelled inside the uterus and deviated head was brought to normal position by holding the mandible. The flexed legs were also brought to normal posture manually by holding them at their toes and extending them towards the birth canal. Then moderate traction was applied on both forelimbs and head and a live fetus was delivered successfully. The placenta was removed partially soon after the delivery of the fetus. Thereafter, the animal was administered with Injection, Dextrose normal saline 5% (2 litre I/V), Streptopencilin (5 g, I/M) and Meloxicam (100 mg, I/M). The treatment was continued for 4 days and follow up of the case showed uneventful recovery.

Careful examination of the removed live male fetus revealed severe reduction of facial features; the calf had a single orbit with fused eye balls (instead of one in typical cyclopia (Fig.1). The eyeballs were not covered by eyelids and both the ears were absent. Muzzle and all the skeletal structures

---

\*Corresponding author: Asloob Ahmad Malik

*E-mail address:* malikasloob@gmail.com

of the nose were absent and the area was covered with skin above the centrally located eye (Fig. 2). The lower jaw was longer than the upper jaw leading to protrusion of tongue from base outside the mouth. The calf had a dome shaped head, centrally located orbit with protruding tongue giving it a monkey face like appearance. The calf was unable to stand after its delivery due to ankylosed limbs. Colostrums was fed to the calf with the help of bottle. The fetus died 8 hours after its successful delivery.



Fig. 1. Cyclopia monster calf

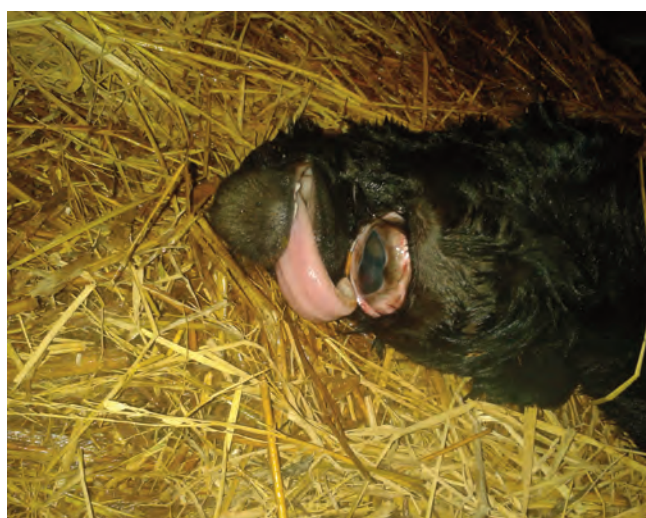


Fig. 2. Showing head region of the cyclopia monster calf.

All the physical characteristics of the deformed fetus were suggestive of a condition known as cyclopia and classified under teratological defects of embryonic development (Roberts, 1971). Ozcan *et*

*al* (2006) reported atypical cyclopia in a brown swiss cross calf with most significant malformations such as the presence of an median orbit like opening that did not contain an eyeball and other defects included brachygnathia superior and arhinia. An unusual case of cyclopia and arhinia monster was also reported in mehsana buffalo (Sutaria *et al.*, 2012). The causes of such fetal monstrosities are not well understood but many substances have been incriminated in their occurrence. In sheep the condition has been reported due to ingestion of *Veratrum Californicum* (Binns *et al.*, 1963). Predominantly certain alkaloids including cyclopamine, 2-deoxyjervine and cyclopassine found in some plants especially *Veratrum spp.* are known to cause cyclopia among other birth defects when consumed during early pregnancy. However, the possible cause of this defect could not be ascertained in the present report.

## References

- Binns, W., James, L.F., Shupe, J.L., Everett, G., 1963. A congenital cyclopic type malformation in lambs induced by maternal ingestion of a range plant *Veratrum Californicum*. *American Journal of Veterinary Research* 24, 1164.
- Honparkhe, M., Ghuman, S.P.S., Malik, A.A., 2009. Dystocia due to cebocephalic emphysemated fetus in a cross-bred heifer. *Internet journal of Veterinary Medicine*. 7(1).
- Kantharaj, S., 2010. An unusual case of schistosomus reflexus with Cyclops in a goat a case report. *Indian Journal of Animal Reproduction* 31(1), 93.
- Ozcan, K., Gürbulak, K., Takçi, I., Ozen, H., Kaçar, C., Pancarci, M.S., 2006. Atypical cyclopia in a brown swiss cross calf: a case report. *Anat. Histol, Embryol.*, 35(3), 152-154.
- Roberts, S.J., 1971. *Veterinary Obstetrics and Genital Disease*. 2nd Edn., CBS Publishers, New Delhi.
- Sutaria, T.V., Sutaria, P.T., Patel, J.S., Chauhan, P.M., 2012. An unusual case of cyclopic and arhinia monster in Mehsana buffalo. *Veterinary World* 5(7), 429-430.