



## Occurrence and Surgical Reconstruction of Perineal Lacerations and Rectovaginal Fistulae in Dairy Cows

Awad Rizk\*, Esam Mosbah

Department of Surgery, Anaesthesiology and Radiology, Faculty of Veterinary Medicine, Mansoura University, 35516 Mansoura, Egypt

### ARTICLE INFO

#### Original Research

#### Received:

19 October 2016

#### Accepted:

25 October 2016

#### Keywords:

Cows  
One-stage repair  
Perineal lacerations  
Primiparous  
Rectovaginal fistula

### ABSTRACT

The objective of this study was to throw light on the occurrence and surgical repair of perineal laceration (PL) and rectovaginal fistula (RVF) in dairy cows. A report of 10 Holstein-Frisian and Holstein dairy cattle, suffering a PL of second degree (2<sup>nd</sup> PL; n=1) and third degree (3<sup>rd</sup> PL; n= 6) as well as RVF (n=3). Surgical repair of the 2<sup>nd</sup> PL and 3<sup>rd</sup> PL was performed by a one-stage Goetz technique. While the repair of RVFs was performed either through a one-stage repair or vaginal approach. Healing of wounds, recovery and complications were recorded. 3<sup>rd</sup> PL in 4 cows (67%) healed by first intention. Three of these cows subsequently became pregnant, while the fourth cow was culled. The laceration of the other two cows (33%) healed except for a small RVF in one cow. The other cow had a first degree perineal laceration (1<sup>st</sup> PL) that healed without surgical intervention. Two fistulae healed completely and the affected cows became pregnant 2 months after surgery. The third cow with fistula showed persisted a 5-6 mm diameter rectovestibular fistula. Complete healing of the case of 2<sup>nd</sup> PL was occurring without complications. It could be concluded that, PL can occur mostly in primiparous cows with difficult assisted deliveries and that one stage repair of PL in cows substantially improves the perineal conformation. The RVF in cows could be corrected either through vaginal approach or a one-stage surgical repair. Breeding after surgical treatment of PL and RVF in dairy cows is advisable.

*J. Adv. Vet. Res. (2016), 6 (4), 123-129*

### Introduction

Rectovaginal and perineum injuries, including rectovaginal fistula (RVF), perineal laceration (PL), pneumovagina, and urovagina cause serious economic losses in dairy cows (Hudson, 1972; Dreyfuss *et al.*, 1990). Lacerations had been classified according to their extent as first, second and third degree lacerations (Aanes, 1964; Dreyfuss *et al.*, 1990; Farag *et al.*, 2000). PLs, which are commonly affecting primiparous females, are associated with obstetrical trauma and particularly during parturition (Dreyfuss *et al.*, 1990; Kazemi *et al.*, 2010). This injury is mainly caused by forced extraction or the expulsive forces generated during labor in the presence of fetomaternal disproportion or fetal malposition (Colbern *et al.*, 1985; Hudson, 1986; Dreyfuss *et al.*, 1990 and Arthur *et al.*, 1996).

Perineal laceration are usually less frequent in cattle compared to mares (Khar *et al.*, 1993; Kazemi *et al.*, 2010). Reports on the surgical corrections of PL in cattle are rare. Therefore,

reconstruction of 3<sup>rd</sup> PL is indispensable to quickly bring the female cattle back to breeding soundness and for cosmetic reasons. A 3<sup>rd</sup> PL results in disruption of the perineal body, anal sphincter, floor of the rectum and ceiling of the vagina leading to a common opening between the vestibule and rectum.

Rectovaginal fistula is an abnormal duct between the rectum and vagina, and usually occurs anterior to the anus and vulva without involvement to these structures. RVF may result from obstetrical trauma, improper repair of 3<sup>rd</sup> PL, trauma during breeding, perineal or perivaginal abscesses and congenital abnormalities (Colbern *et al.*, 1985; Dreyfuss *et al.*, 1990). PL and RVF lead to a connection between the rectum and the vaginal vestibule resulting in fecal contamination of the vagina. During estrus, the cervix undergoes relaxation and therefore, endometritis develops with subsequent decrease in the future fertility (Dreyfuss *et al.*, 1990; Farhoodi *et al.*, 2000).

Numerous surgical techniques and modifications have been reported for the repair of PL in mare. However, rare cases were reported in cattle. 3<sup>rd</sup> PL are most commonly repaired by the Goetz one-stage surgical technique (Dreyfuss *et al.*, 1990; Farag *et al.*, 2000; El Maghraby, 2002; Karrouf and Zaghoul, 2003), the Aanes two-stage technique (Aanes, 1964; Colbern

\*Corresponding author: Awad Rizk  
E-mail [awad\\_surgery@yahoo.com](mailto:awad_surgery@yahoo.com):

et al., 1985 ;El-Seddawy, 1993) or a modification of these techniques (Woodie, 2006; Mosbah, 2012; Seabaugh and Schumacher, 2014; Anand and Singh, 2015; Elkasapy and Ibrahim, 2015). The goal of any surgical repair is to establish a functional partition between the rectum and the vaginal vestibule, and to restore a functional perineal body. This will prevent further contamination and permit treatment of vaginitis, cervicitis and metritis, which lead to infertility. Given the expected economic losses of animal production, it is necessary to find the suitable surgical procedure that can successfully restore the fertility of affected animals (Dreyfuss et al., 1990; Farhoodi et al., 2000).

Recently, little information and few reports were recorded on the surgical correction of PL in cows. Additionally, since reconstruction of 3<sup>rd</sup> PL and RVF appears necessary to quickly bring the female cows back to breeding soundness, therefore, this retrospective report was performed to shed a new light on the occurrence of PL and RVF as well as the evaluation of a one-stage technique for their repair in dairy cows.

## Materials and methods

### Animals

A total number of 10 female, Holstein –Frisian and Holstein, dairy cows, ranged in age from 2.5-5 years old were included. They suffered a PL of 2<sup>nd</sup> degree (n= 1) and 3<sup>rd</sup> degree (n= 6) as well as RVF (n=3). The cases were five primiparous and five multiparous cows. These cases were referred to the surgery clinic of the Faculty of Veterinary Medicine, Mansoura University, Mansoura, Egypt and from private farms in Damietta and Dakahlyia Governorates, Egypt.

All affections occurred following parturition and they were manipulated 2-4 months after injury. Vaginal and uterine infections were controlled before surgical intervention. Prophylactic doses of broad-spectrum antibiotics and a non steroidal anti-inflammatory flunixin meglumine (2.2 mg/kg intravenously [IV], Flamicure, Pharma Swede, Egypt) were administered.

### Anesthesia and surgical intervention

Surgical repair was postponed until complete healing of the original injury (Figs. 1 and 2 A- B), which was usually within 8-16 weeks after laceration (Table1).

All cows were kept off food for 24 hours and water was withheld for 12 hours prior to surgery to minimize fecal contamination during surgery.

The animal was restrained in the stanchion, and the surgical repair was performed in the standing position under the effect of posterior epidural analgesia using a combination of xylazine HCL sedation (0.03 mg/kg body weight, Xylaject, ADWIA, Cairo, Egypt), and lidocaine HCl (0.2 mg/kg, Debocaine, 20mg/ml, Aldebiky, Egypt) according to Lee and Yamada (2005).

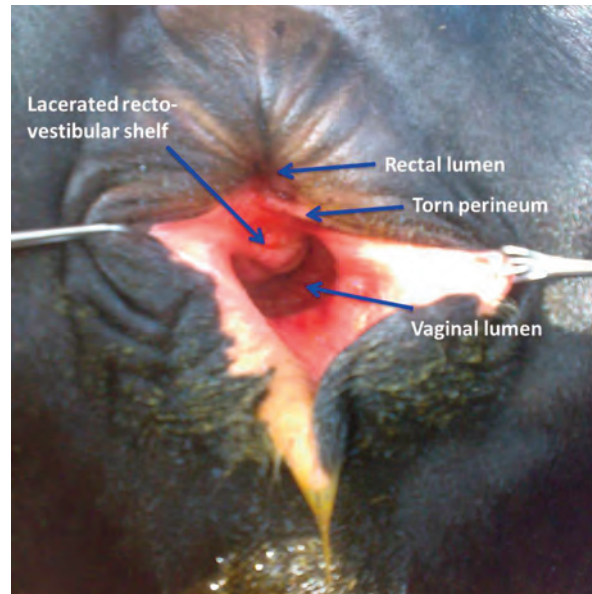


Fig. 1. A three years old cow suffered PL 6 weeks post labor after subsiding of inflammation and edema.

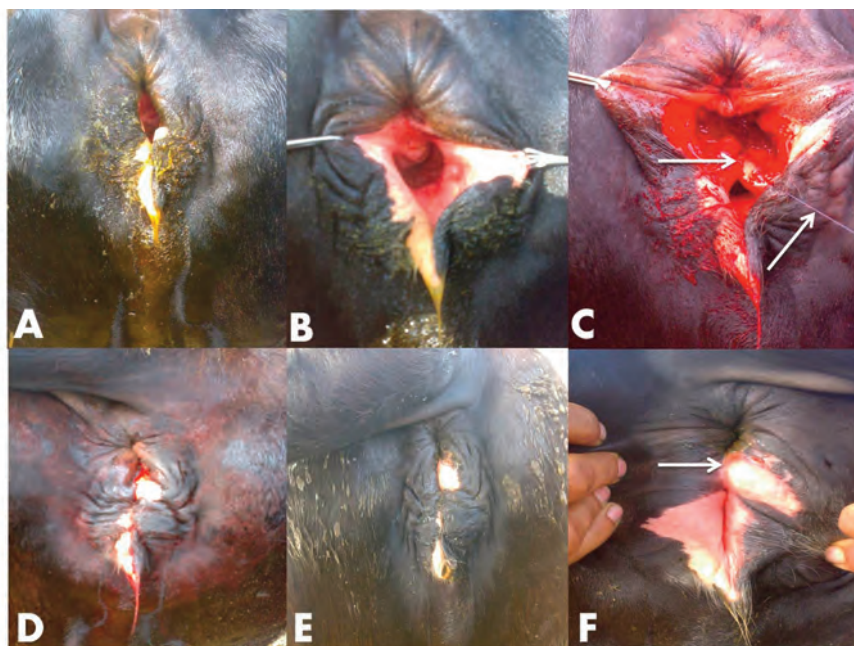


Fig. 2. Showing a 3<sup>rd</sup> PL in a primiparus Holstein-Frasian cow (A& B); after dissection a long the rectovaginal septum and reconstruction (arrow) with PDS suture (white arrow; C); after closure of recto-vestibular septum and perineal body (D); showed complete healing of perineal body 3 months post-operatively (E&F).

Table 1. Signalment, length of laceration, interval between injury and repair and outcome in cows with perineal lacerations (n=7) and rectovaginal fistulae (n=3)

Nr.	Cows			Type of perineal injury	Length of injury (cm)	Interval between injury&repair (Mo)	Surgical technique	PO complications	Interval between repair and breeding
	Breed	Age(yr)	Parity						
1	HF	3	2 <sup>nd</sup>	RVF	4	2	Modified one-stage	5-6mm fistula persisted	3.5 months
2	HF	5	2 <sup>nd</sup>	3 <sup>rd</sup> PL	4	2	Modified one-stage	Edema of perineum	3 months
3	HF	4	2 <sup>nd</sup>	RVF	4	2.5	Vaginal approach	None	2months
4	H	4	1 <sup>st</sup>	3 <sup>rd</sup> PL	8	2	Modified one-stage	None	2months
5	HF	4.5	1 <sup>st</sup>	3 <sup>rd</sup> PL	13	3	Modified one-stage	Chronic metritis	None (culled)
6	H	4	2 <sup>nd</sup>	2 <sup>nd</sup> PL	8	4	Goetz one-stage	Recurrence	Culled (infertility)
7	HF	3	1 <sup>st</sup>	3 <sup>rd</sup> PL	10	2	Modified one-stage	Small RVF	4 months
8	H	5	2 <sup>nd</sup>	RVF	2	4	Vaginal approach	None	2 months
9	HF	2.5	1 <sup>st</sup>	3 <sup>rd</sup> PL	5	3	Modified one-stage	1 <sup>st</sup> PL	3 months
10	HF	3	1 <sup>st</sup>	3 <sup>rd</sup> PL	6	2	Modified one-stage	None	2 months

HF= Holstein-Frasian

RVF= Rectovaginal fistula

H= Holstein

PL= Perineal laceration

Mo= month

PO= post-operative

The tail of the animal was bandaged and tied to one side. Aseptic preparation of the perineal region was performed.

For 3<sup>rd</sup> PL, a modified one-stage surgical repair technique was used for suturing and closure of the lacerations according to Adams and Fessler (2000). Briefly, the operative area was exposed by holding the skin with Allis tissue forceps near the muco-cutaneous margin on each side of the disrupted dorsal commissure of the vulva (Fig. 1). An incision was performed through the scar tissue line at the junction between the vestibule-vagina and rectum to separate the vestibular and rectal mucous membranes in a horizontal manner from the skin caudally to the intact perineal body cranially. The incision was deepened about 4-5 cm in the normal tissue. All the suture lines were started in the rostral aspect of the laceration and continued caudally using size 1 polydioxanone (Unicryl M, Unimed, Kingdom of Saudi Arabia). Firstly, a continuous horizontal mattress pattern was used for suturing of the vestibular flap (Fig. 2C). Secondly, the perineal body was sutured using simple interrupted suture. Shelf reconstruction was accomplished by suturing the rectal mucosa as a third line using a continuous horizontal mattress suture with the mucosa everted in the rectal lumen. The rest perineal tissues together with the skin were sutured by interrupted vertical mattress sutures using size 0 prolene (Fig. 2D).

For 2<sup>nd</sup> PL, an incision was made along the scar tissue line at the junction between the vaginal vestibule and rectum. Dissection of the rectovestibular shelf was started cranially on a frontal plane and laterally into the submucosal tissues as well as caudally to the level of the perineal skin. Lateral dissection

was continued until the two flaps were created and brought to the midline without any tension (Fig. 3C). Closure suture was made according to the modified one-stage repair by Goetz technique (six-bite vertical mattress suture pattern; Fig. 3D).

For RVF, surgical repair was performed through the vagina in low RVF (n= 1; Fig. 4C) while the high RVF (n= 2) was repaired through a one-stage surgical repair technique.

#### Post-operative care

Administration of antibiotics was continued for 48 hours and a single dose of flunixin meglumine (2.2 mg/ kg IV; Finadyne, Intervet, Germany) was administered.

The owner was advised to feed only a small quantity of green hay every day throughout the postoperative period and if needed careful manual emptying of the rectum was advised

Skin sutures were removed 10-14 days after surgery. A gentle digital examination of the surgical site from the vaginal side was recommended 2 weeks after surgery to assess healing. Rectal examination was not performed for a minimum 30 days after surgery. Uterine evaluation and treatment of metritis, if present, was recommended prior to any attempts at breeding.

#### Follow-up and outcome

Wounds healing, recovery and complications were recorded. Following healing, the operated cows were examined for

metritis and treated accordingly. Moreover, conception rate after natural mating or artificial insemination was recorded.

## Results

### Third degree perineal laceration (n= 6)

Six dairy cows (Five Holstein-Frisian and one Holstein) ranged in age from 2.5-5 years old, including five first calf cows, had a 3<sup>rd</sup> PL that occurred at calving and a cow had it in the second labor. The time from injury to presentation ranged from 2- 3 months. Lacerations ranged from 4-13cm long (Fig. 2B). Surgical repair of the lacerations was performed in all cows (Table 1).

Following surgery, the healing rate in 3<sup>rd</sup> PL in four cows was 67% after first intention (Figs. 2E-F). Three of these cows were artificially inseminated and subsequently became pregnant and had normal vaginal deliveries. The fourth cow in which laceration healed by first intention was culled because of infertility associated with chronic metritis. The laceration of the other two cows (33%) healed except for a small RVF in one cow, that became pregnant and delivered a calf despite this defect. The other cow had a 1<sup>st</sup> PL and healing was achieved without surgical intervention. One cow had an edema at the perineum in the postoperative period, which subsequently subsided within a few days. A total of 5 cows (83.3%) in which surgery of the 3<sup>rd</sup> PL was performed remained fertile. None of these cows that delivered calves sustained another PL.

### Second degree perineal laceration (n= 1)

A Holstein cow of 4 years old had a 2<sup>nd</sup> PL that occurred during the second labor. The time from the injury after partu-

rition to presentation was 4 months (Table 1), which was observed by a veterinarian during rectal examination.

Examination of the perineal region revealed a tear measured 8cm long, which extends from the ventral aspect of the anus to the dorsum of the vulva and vagina, and the perineal body is partially intact, without RVF (Figs. 3A-B). Surgical repair was successfully performed by a one-stage Goetz surgical repair technique. Complete healing of the laceration was achieved without obvious complications. The owner informed us 6 months later that the operated cow was culled from the herd.

### Rectovaginal fistulae (n= 3)

Two Holstein dairy cows had rectovaginal fistulae and a Holstein Frisian cow had a rectovestibular fistula. All cows were adult and aged 3-5years old; they were diagnosed after the second labor (Table 1). Clinical examination, revealed acquired RVF ranged from 2-4 cm in diameter with intact perineal body (Figs. 4A-B). Surgical correction of the rectovaginal fistulae was performed through vaginal approach, while the case of rectovestibular fistula was corrected through a modified single-stage technique.

Following surgery, two fistulae healed completely and in one cow, a 5-6 mm diameter rectovestibular fistula persisted, this cow became pregnant via artificial insemination on the 5th estrus cycle following treatment of metritis. The two cows, in which fistulae healed completely became pregnant 2 months after surgery and they remained fertile and delivered vaginally without complications. A total of 3 cows became fertile after surgical repair of RVF, none of these cows that delivered calves sustained a PL in the following parturitions.

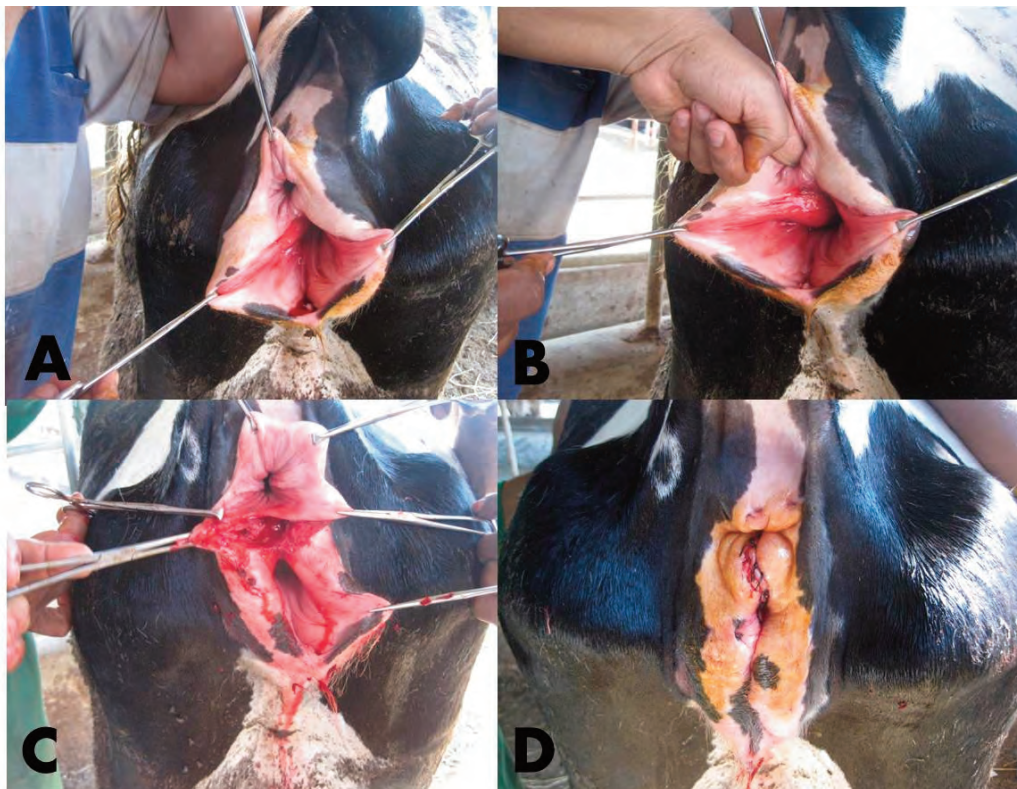


Fig. 3. Showing a 2<sup>nd</sup> PL in multiparous Holstein cow with partial intact of the perineal body (red arrow; A); no rectovaginal fistula (operator finger; B); the dissection was performed to create large rectal and vestibular flaps (C); after closure of rectovestibular septum and perineal body (D).

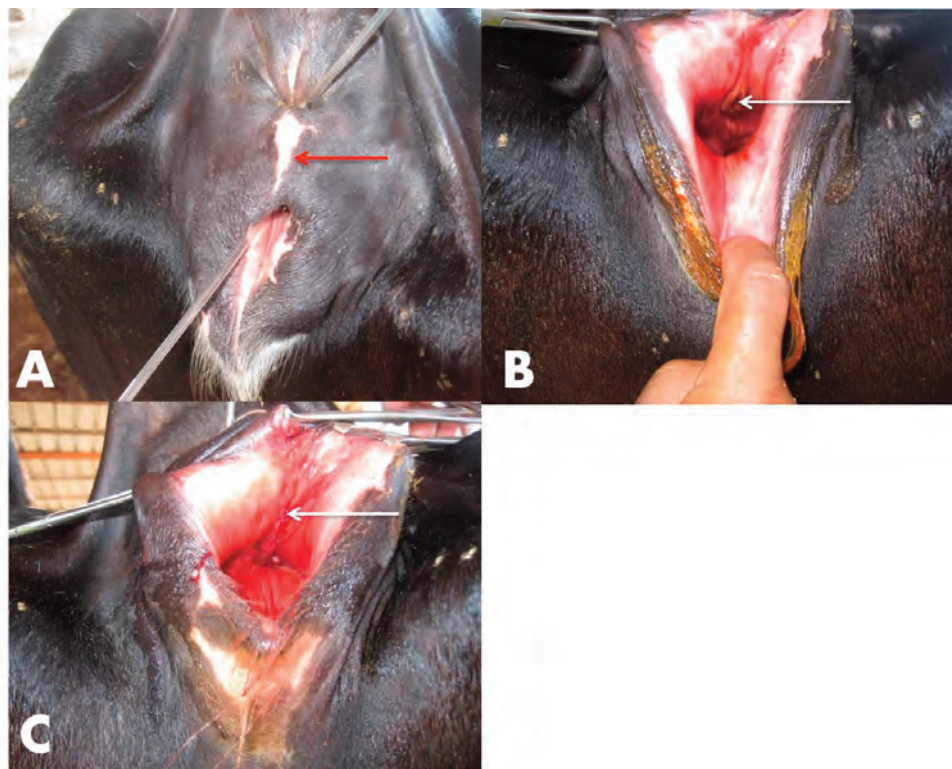


Fig. 4. Showing a RVF in a primiparus Holstein cow with intact perineal body (red arrow; A); appearance of the fistula per vagina (B); after correction of the fistula through vaginal approach (white arrow, C).

## Discussion

Perineal lacerations are classified from first to third degrees. 1<sup>st</sup> PL involves only the skin and vulvar mucous membrane. 2<sup>nd</sup> PL involves the skin, mucous membrane, the perineal body and constrictor vulvae muscle, while, 3<sup>rd</sup> PL involves structures damaged in the 2<sup>nd</sup> PL, plus the anal sphincter and all tissues between the vagina and the rectum (Aanes, 1964; Colbern *et al.*, 1985; Dreyfuss *et al.*, 1990).

Based on the results of the present study, successful reconstruction of 3<sup>rd</sup> PL and RVF by a modified one-stage surgical repair offered considerable promise for good reproductive performance in cows. The suturing series used to create a thick vestibular and perineal shelf, and then the rectal mucosa was sutured over the shelf with everted edges as a seal against gross contamination. Similar technique was used for surgical repair of the third degree rectovestibular laceration in mare with successful outcome (Adams and Fessler, 2000).

Since there are a few reports on the surgical reconstruction of PL in cows, it is interesting to record and to evaluate the outcome of the cases of PL and RVF in dairy cows, as well as its relation to reproductive performance. Cows suffered PL in the present study had a history of forceful extraction of fetus during a difficult parturition, and most of feti being males. Male calf deliveries produced high risk of rectovaginal injuries, because males typically are heavier than females, so they cause more dystocia and damage to the birth canal. Similar origins of perineal lacerations in mares have been described previously (McKinnon and Vasey, 2007).

The first-calf cows and primiparous mares are by far the most commonly affected by 3<sup>rd</sup> PL. This finding was confirmed in cows by Hudson (1972); Dreyfuss *et al.*, (1990) and El-Seddawy (1993) who stated that, it is extremely rare for a cow to sustain 3<sup>rd</sup> PL when the calving is unassisted. 3<sup>rd</sup> PL is rare in cows owing to their less violent expulsive efforts at parturition (Shires, 1991). In contrary, this affection occurs more com-

monly in mares due to the forceful uterine contractions and abdominal bouts in addition to the uncorrected malposition which pass the foal's foot through the vaginal roof (Aanes, 1964; O'Rielly *et al.*, 1998; McKinnon and Vasey 2007; Kazemi *et al.*, 2010).

It has been suggested that surgery of 3<sup>rd</sup> PL should be postponed for at least 4-6 weeks from initial injury. Immediate repair of lacerations are generally unsuccessful due to the accompanied edema and inflammation of lacerated tissue which rapidly widen and lengthen the wound (Desjardins *et al.*, 1993; LeBlanc, 1999, Woodie, 2006). Such a delay permits epithelial re-growth to cover the damaged tissue.

Reconstruction of PL and RVF were performed in a standing position under the effect of caudal epidural anesthesia with all structures supported in proper relation. In addition to the prolonged analgesia, about four hours, produced from epidural injection of xylazine Hcl and lidocaine Hcl. These findings agree with that reported in mares by Farag *et al.*, (2000); Mosbah (2012) and in cows by Dreyfuss *et al.*, (1990); El-Seddawy (1993).

Although many authors differ in their approach to repair PL in mares, the objective of all procedures was to rebuild the shelf of tissue between the rectum and the vestibule, and to restore the structural integrity of the perineal body. In the present study, third degree perineal lacerations in cows were successfully repaired by a one-stage repair technique. A similar technique was performed in mare and cows (Dreyfuss *et al.*, 1990; Phillips and Foerner, 1998; LeBlanc, 1999; McKinnon and Vasey, 2007; Mosbah, 2012) and this technique offered improved fertility and conformational soundness in the perineal area.

Previous studies in mares have shown that endometritis could subside within 15 days after recto-vestibular repair and breeding could be allowed by artificial insemination (Schumacher and Blanchard; 1992; Mosbah, 2012; Elkasapy and Ibrahim, 2015). Studies also showed that subsequent fertility in mares and cows could be improved as evidenced by the

significant increase of pregnancy rates (62.5 to 75 %) in mares (Kasikci *et al.*, 2005; Kazemi *et al.*, 2010; Elkasapy and Ibrahim, 2015) and (71 %) in cows (Dreyfuss *et al.*, 1990) following one stage surgical repair. In the present report, five cows (83.3%) that had undergone surgery became pregnant suggesting that the used technique could be efficiently employed in cows with 3<sup>rd</sup> PL. The perineal conformation was improved in all cows that underwent surgical repair.

One cow of 3<sup>rd</sup> PL showed a small rectovestibular fistula after healing. In cows, endogenous uterine defense mechanisms combined with intrauterine therapy are sufficient to overcome the continued fecal contamination. If the surgical repair does not heal completely, it may still reduce fecal contamination to a level that no longer affects fertility as explained by Dreyfuss *et al.*, (1990) in cows and Anwer and Purohit, (2013) in camel. Another cow from those suffered a 3<sup>rd</sup> PL showed a 1<sup>st</sup> PL that healed without surgical intervention. A third cow had an edema of the perineal area in the postoperative period which subsequently subsided gradually within few days.

Period relevance of rectovaginal injuries was the highest in first calf heifers (Roberts, 1986; Dreyfuss *et al.*, 1990; Lafi and Kaneene, 1992; Arthur *et al.*, 1996). Some authors stated that the occurrence of RVF is rare in cows (Roberts, 1986; Arthur *et al.*, 1996). The RVF results from disruption of the tissue between the vestibule and the rectum without disruption of the perineal body, anal sphincter or constrictor valvae muscle muscle (Aanes, 1964; Colbern *et al.*, 1985; Dreyfuss *et al.*, 1990).

The RVF is usually congenital in nature and may be acquired. The acquired one may develop probably due to forceful traction of the foetus in dystocia cases, trauma by obstetrical pointing instruments and extensive thinning of the rectal mucosa (Arthur *et al.*, 1996). Our cases of RVF were acquired post second labor. In this study, two RVF were successfully surgically closed through vaginal approach and healed completely. The third fistula was surgically repaired by a modified single-stage technique. This cow had a persistent 5-6 mm diameter fistula after healing. However, in spite the presence of a small fistula, the cow became pregnant by artificial insemination on the 5th estrous cycle.

In spite of successful surgery and healing in the case of 2<sup>nd</sup> PL, the owner of the cow informed us 6 months later that such cow was culled from the herd due to poor reproductive performance.

A polydioxanone suture material was used for repairing PL and RVF in our cases due to its strength, delayed absorbability and its excellent tissue compatibility. Various suture materials have been used for repair of third-degree rectovestibular lacerations in mare, such as monofilament nylon (Stickle *et al.*, 1979), chromic cat gut (Colbern *et al.*, 1985), polyglycolic acid (Shokry *et al.*, 1986), polyglactin 910 (Mehrerjedi *et al.*, 2010), and polydioxanone (Adams and Fessler, 2000; Mosbah, 2012) and in cows, such as polygalactin 910 (El-Seddawy, 1993), chromic cat gut (Dreyfuss *et al.*, 1990).

In contrast to mares, which have a 15 to 75% recurrence rate of perineal lacerations after foaling (Aanes, 1964; Colbern *et al.*, 1985), none of our cows that subsequently delivered a calf per vagina sustained another perineal laceration. Many factors may account for this difference. Most cows continue to grow and mature physically between their first and second pregnancies than mares do. Following a perineal laceration caused by dystocia, the dairy farmers may choose to breed affected cows to bulls that rate higher in calving ease and lower in calf birth weight. It is difficult to determine whether less scar tissue formation and loss of elasticity occur following wound repair in cows, but this may also be a factor (Dreyfuss *et al.*, 1990; Farhoodi *et al.*, 2000). Artificial insemination ex-

pedites breeding in the cow because of decreased concern that breeding trauma might disrupt surgical repair (Dreyfuss *et al.*, 1990).

## Conclusion

This study shows that PL can occur mostly in primiparous dairy cows with assisted difficult deliveries, and that the used technique for treatment of PL in cows substantially improves the perineal conformation with subsequent improving their fertility. The high RVF in cows could be corrected through a vaginal approach while the low one could be repaired with a single-stage surgical technique. Lastly, breeding after surgical treatment of PL and RVF in dairy cows is usually advisable.

## Acknowledgement

The authors would like to sincerely thank Dr. Mohamed Mosbah, Mansoura Animal Research Institute for his assistance during care of the operated cows in dairy farms.

## References

- Aanes, W.A., 1964. Surgical repair of third degree perineal laceration and rectovaginal fistula in the mare. *Journal of American Veterinary Medical Association* 144, 485-491.
- Adams, S.B., Fessler, J.F., 2000. Third-degree perineal laceration repair. In: *Atlas of equine surgery*, 1<sup>st</sup> ed. Philadelphia, London, Toronto, Sydney: W.B. Saunders Co, pp. 241-244.
- Anand, A., Singh, S.S., 2015. Inside-out continuous suturing technique for the repair of third-degree perineal laceration in mares. *Journal of Equine Veterinary Science* 35(2), 147-152.
- Anwer, S., Purohit, G.N., 2013. Occurrence and surgical repair of third degree perineal lacerations in adult female camel (*Camelus dromedarius*) by one-stage (Goetz) technique. *Open Veterinary Journal* 3(2), 75-79.
- Arthur, G.H., Noakes, D.E., Pearson, H., 1996. Perineal injuries at parturition. In: *Veterinary Reproduction and Obstetrics*. 7th Edition. Bailliere Tindall, London, pp. 279-284.
- Colbern, G.T., Aanes, W.A., Stashak, T.S., 1985. Surgical management of perineal lacerations and rectovestibular fistulae in the mare: a retrospective study of 47 cases. *Journal of American Veterinary Medical Association* 186, 265-269.
- Desjardins, M.R., Trout, D.R., Little, C.B., 1993. Surgical repair of rectovaginal fistulae in mares: twelve cases (1983-1991). *Canadian Veterinary Journal* 34, 226-231.
- Dreyfuss, D.J., Tulleners, E.P., Donawick, W.J., *et al.*, 1990. Third-degree perineal lacerations and rectovestibular fistula in cattle: 20 cases (1981-1988). *Journal of American Veterinary Medical Association* 196, 768-770.
- El Maghraby, H.M., 2002. A retrospective study on some surgical affections of the perineum and vagina in farm animals. *Zagazig Veterinary Journal* 30(30), 84-100.
- Elkasapy, A.H., Ibrahim, I.M., 2015. Contribution to reconstruction of third degree rectovestibular lacerations in mares. *Open Veterinary Journal* 5(1), 23-26.
- El-Seddawy, D.F., 1993. Surgical repair of perineal laceration in mares and frasian cows. *Journal Egyptain Veterinary Medical Association* 53(4), 681-690.
- Farag, K.A., Berbis, E.A., Ghoneim, I.M., 2000. A one-stage repair of third degree rectovestibular lacerations in the mare: an experimental and clinical study. *Journal Egyptain Veterinary Medical Association* 60, 143-151.
- Farhoodi, M., Nowrouzian I, Hovareshti P., 2000. Factors Associated with Rectovaginal Injuries in Holstein Dairy Cows in a herd in Tehran, Iran. *Prevent Vet. Med.* 46, 143-148.
- Hudson, R.S., 1972. Repair of perineal laceration in the cow. *Bovine Practice* 7, 34-36.
- Hudson, R.S., 1986. Genital surgery of the cow. In: *Current Therapy in Theriogenology*. Morrow, D.A. (Ed.), Vol. 2. Saunders, Philadelphia, PA, pp. 341-346.
- Karrouf, G.I.A., Zaghoul, A.E., 2003. Surgical correction of third-degree rectovestibular lacerations in equine. *Mansoura Veterinary*

- Medical Journal VI (2),95-110.
- Kasikci, G., Huriye, H., Alkan, S., 2005. A modified surgical technique for repairing third degree perineal lacerations in mares. *Acta Vet. Hung.* 53, 257-264.
- Kazemi, M.H., Sardari, K., Emami, M.R.,2010. Surgical repair of third degree perineal laceration by Goetz technique in the mare: 7 cases (2000-2005). *Iranian Journal of Veterinary Research* (11) 2, 184-188.
- Khar, S.K., Mannari, M.N., Singh, J.,1993. Perineal lacerations. In Tyagi RPS, Singh J (Eds.): *Ruminant Surgery*, 1<sup>st</sup> edition. Delhi: CBS publishers and Distributors, pp. 295-297.
- Lafi, S.Q., Kaneene, J.B.,1992. Epidemiological and economic study of the repeat breeder syndrome in Michigan dairy cattle. *Prev. Vet. Med.* 14, 87-98.
- LeBlanc, M.M.,1999. Diseases of the vagina, vestibule and vulva. In: *Equine Medicine and Surgery*. Colahan PT, Mayhew IGG, Merritt, A.M., Moore, J.N., editors., 5th ed. St. Louis, MO: Mosby, pp. 1175-1193.
- Lee, I., Yamada, H., 2005. Epidural administration of fixed volumes of xylazine and lidocaine for anesthesia of dairy cattle undergoing flank surgery. *Journal of American Veterinary Medical Association* 227(5),781-784.
- McKinnon, A.O., Vasey, T.R., 2007. Selected reproductive surgery of the broodmare. In: Samper JC, Pycocck JF, McKinnon AO Eds. *Current Therapy in Equine Reproduction*. Saunders Elsevier Missouri USA, pp. 146-160.
- Mehrjerdi, K.H., Sardari, K., Emami, M.R., 2010. Surgical repair of third-degree perineal laceration by Goetz technique in the mare: 7 cases (2000- 2005). *Iranian J. Vet. Res.*11,184-188.
- Mosbah, E., 2012. A modified one-stage repair of third-degree rectovestibular lacerations in mares. *Journal of Equine Veterinary Science* 32, 211-215.
- O’Rielly, J.L., Mac Lean, A.A., Lowis, T.C., 1998. Repair of third degree perineal laceration by a modified Goetz technique in 20 mares. *Equine Veterinary Education* 10, 2-7.
- Phillips, T.N., Foerner, J.J.,1998. Semitransverse closure technique for the repair of perineal lacerations in the mare. *AAEP Proceedings* 44, 191-193.
- Roberts, S.J.,1986. Diseases of the puerperal period-Rupture of the perineum and vulva. *Veterinary Obstetrics and Genital Diseases (Theriogenology)*. Edwards Brothers, Woodstock, VT, pp 553-556.
- Schumacher, J., Blanchard, T.,1992. Comparison of endometrium before and after repair of third degree rectovestibular laceration in mares. *Journal of American Veterinary Medical Association* 200, 1336-1338.
- Seabaugh, K.A., Schumacher, J.,2014. Urogenital surgery performed with the mare standing. *Vet. Clin. North Am. Equine Pract.* 30, 191-209.
- Shires, M.,1991. Some surgical procedures: Female urogenital system of adult ruminant. 19th ACVS veterinary symposium, San Francisco, California, pp. 276-278.
- Shokry, M., Ibrahim, I.M., Ahmed, A.S., 1986. Preferred suture material in repair of rectovestibular lacerations in mares. *Mod. Vet. Pract.* 67, 546.
- Stickle, R.L., Fessler, J.F., Adams, S.B.,1979. A single-stage technique for repair of rectovestibular lacerations in the mare. *Veterinary Surgery* 8, 25-27.
- Woodie, B., 2006. The vulva, vestibule, vagina and cervix. In: *Equine Surgery*, Auer JA, Stick JA, editors. 3<sup>rd</sup> ed. Philadelphia, PA: W.B. Saunders Co, pp. 845-852.