

Chip Fracture of the Proximal Phalanx in Hard Working Donkeys

M.A. Semieka¹, M.A. Sadan^{2*}, T. N. Misk³

¹Department of Animal Surgery, Faculty of Veterinary Medicine, Assiut University, Egypt.

²Department of Animal Surgery, Faculty of Veterinary Medicine, South Valley University, Egypt

³Department of Animal Surgery, Faculty of Veterinary Medicine, Minoufiya University, Egypt

(Received 20 April 2012/ Accepted 27 September 2012)

Abstract

The present study was carried out in six mature hard working donkeys of both sexes. They were selected from the clinical cases admitted to the Veterinary Medicine Teaching Hospital, Assiut University during the period of 2007-2010. These animals suffering from chip fracture of the proximal phalanx. Diagnoses of the cases were depending on history, clinical examination and radiographic description. Surgical removal of the bone fragment was performed in all cases. Follow up of the cases revealed satisfactory results without any postoperative complications.

Keywords: Chip fracture; proximal phalanx; hard working donkeys

Introduction

Chip fractures are small fragments that usually result from direct bone trauma or hyperextension. Generally, chip fracture may describe any small fracture fragment (Thrall, 1994). Chip fractures of the dorsal proximal margin of the proximal phalanx occur in racehorses and other horses that perform strenuous activities (Jennings, 1984; Elce and Richardson, 2004). Radiographs are required to confirm the diagnosis of chip fracture as well as to check for other causes of fetlock lameness including osselets, sesamoiditis and sesamoid bone fractures (Jennings, 1984).

Surgical or arthroscopic removal of chip fracture is considered to be good methods for treatment of such type of fractures (Jennings, 1984; Elce and Richardson, 2004).

The present study deals with diagnosis and surgical treatment of chip fractures of the proximal phalanx in hard working donkeys.

Materials and methods

The present study was carried out on six mature hard working donkeys of both sexes. The animals

were selected from the clinical cases admitted to the Veterinary Teaching Hospital, Assiut University during the period of 2007-2010. These animals were suffering from chip fractures of the proximal phalanx (Figs. 1, 2, 3). . Diagnosis of the cases based on case history, clinical signs and radiography. Two radiographic projections were obtained, lateral and dorsopalmar. Exposure factors were 15-20 mAs and 48-50 K.V. at a distance of 20 cm. Standard speed film and intensifying screens were used.

Chip fractures of the proximal phalanx were treated by a surgical removal of the bone fragment in all affected cases. The surgery was performed under the effect of chloral hydrate / barbiturate combination. Chloral hydrate 10% solution was injected I.V. in a dose rate of 50 mg/kg.b.wt., followed by injection of thiopental in a dose rate of 5 mg/kg.b.wt. , surgical anesthesia was maintained by injection of thiopental in a dose rate of 1 mg/kg.b.wt. (Hall *et al.*, 2001).

Lateral recumbancy was performed and the site of operation was aseptically prepared. Tourniquet was applied proximal to the fetlock joint. Skin incision at the level of the fractured bone was created. The subcutaneous fascia is incised and the incision is continued deep through the joint capsule. The fetlock joint is placed in flexion and the chip fracture carefully dissected off the parent portion of the bone and removed. The joint capsule, subcutaneous

*Corresponding author: M.A. Sadan

E-mail address: madehsadan@yahoo.com

tissues and skin can be sutured separately. The limb was bandaged for 3-4 weeks (Jennings, 1984). Postoperative radiographs were obtained in all cases to document chip fracture removal.

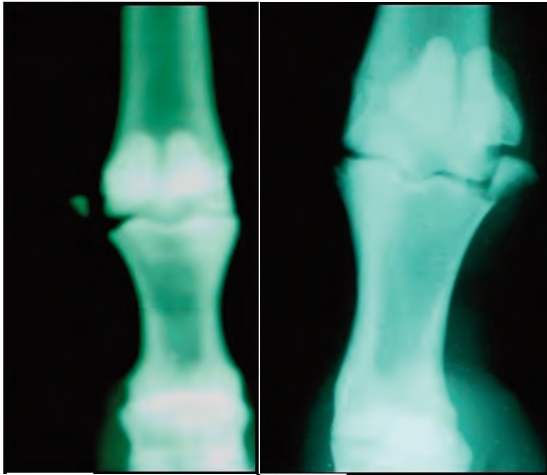


Fig. 1. Dorsopalmar radiographs of the metacarpophalangeal region reveals chip fracture of proximal phalanx.

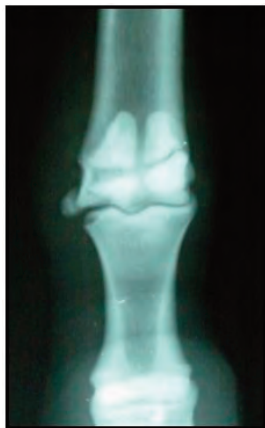

Fig. 2. Dorsopalmar radiograph of the metacarpophalangeal region reveals chip fracture of the proximal phalanx with midbody fracture of the proximal sesamoid bones.

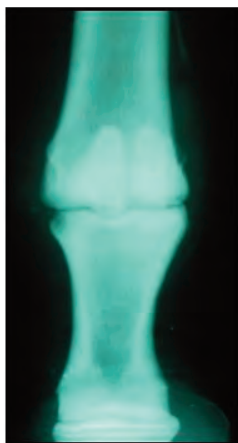


Fig. 3. Dorsopalmar radiograph of the metacarpophalangeal region reveals the site of chip fracture following removal of the bone fragment.

Results

History of the cases indicated that the donkeys were mature hard working and they exposed to severe trauma at the level of the fetlock joint. Clinical examination revealed lameness, painful during palpation and flexion of the fetlock joint and over all enlargement of the joint.

Radiographic examination revealed presence of chip fracture on the dorsomedial aspect of the first phalanx in the right thoracic limb in 3 cases, on the dorsomedial aspect of the first phalanx in the left thoracic limb in 2 cases and on the dorsolateral aspect of the first phalanx in the right pelvic limb in one case. Follow up the cases showed good healing and the animals returned to work and performed well.

Discussion

Proximal phalangeal fractures occur in many configurations, ranging from chip fractures to severely comminuted fractures (Dechant and Macdonald, 1998). In the present study chip fractures of the proximal phalanx in hard working donkeys is considered to be uncommon where it diagnosed only in six cases while the most types of proximal phalanx fractures were comminuted. This because the hard working donkeys exposed to severe traumatic factors as accident leading to comminuted fracture of the proximal phalanx.

Radiograph is essential for diagnosis and description of proximal phalanx fractures (Zert *et al.*, 2007; Bukowiecki *et al.*, 2008). Radiographic description revealed that, the chip fracture of the proximal phalanx in horse may affect the dorsomedial aspect of the thoracic limbs, dorsomedial and dorsolateral aspect of the pelvic limb. The most common type of chip fracture is that affect the dorsomedial aspect of the proximal phalanx in the left thoracic limb (Elce and Richardson, 2004). In the present study chip fractures were diagnosed affect the dorsomedial aspect of the proximal phalanx of the thoracic limbs in 5 cases and affect the dorsolateral aspect of the proximal phalanx of the pelvic limb in one case. This may be due to the dorsomedial aspect of the proximal phalanx of the thoracic limb were exposed to traumatic factors.

Arthroscopic removal is the surgical treatment of choice for horses with chip fractures of the dor-

soproximal aspect of the proximal phalanx (Elce and Richardson, 2004). According to the present study, chip fractures of the proximal phalanx in donkeys were treated by surgical removal of the bone fragment with satisfactory results.

Conclusion

Chip fractures of the proximal phalanx in donkeys were uncommon and affect mainly the dorsomedial aspect of the proximal phalanx of the thoracic limbs. Surgical removal of chip fracture is a good method for treatment of this type of the proximal phalanx fracture.

References

- Bukowiecki, C.F., Bramlage, L.R., Gabel, A.A., 2008. Palmar / planter process fractures of the proximal phalanx in 15 horses. *Veterinary Surgery* 15 (5), 383-388.
- Dechant, J.E., Macdonald, D.G., 1998. Repair of complete dorsal fracture of the proximal phalanx in two horses. *Veterinary Surgery* 27, 445 - 449.
- Hall, L.W.; Clark, K.W., Trim, C.M., 2001. *Veterinary anesthesia* W.B. Saunders. London New York Philadelphia, Tenth edition. pp. 296
- Jennings, P.B., 1984. *The practice of large animal surgery*. W.B. Saunders Company. Philadelphia London Tokyo, Volume II, pp. 844-846.
- Richardson, D.W., Elce, Y.A., 2004. Arthroscopic removal of dorsoproximal chip fractures of the proximal phalanx in standing horses. *Veterinary Surgery* 31 (3), 195-200.
- Thrall, D.E., 1994. *Text book of veterinary diagnostic radiology*. W.B. Saunders Company. Philadelphia London Tokyo, 2nd Edition, p. 107.
- Zert, Z.; Mezerova, J.; Kabes, R., Krisova, S., 2007. Sagittal fracture of the proximal phalanx in a horse complicated during induction of anesthesia by complete fragmentation of the bone: a cases report. *Veterinarni Medicina* 52 (2), 79 - 82.