

Effect of dietary probiotic supplementation on blood parameters, behavior and health performance of broilers

Mona A.M. El Sayed¹, Moataz A.M. Abdelrahman², Madeha H.A. Darwish¹, Ahmed A.A. Mohammed¹, Eman A. Negm^{3*}, Nada A. Abdelsamea⁴

¹Department of Animal and Poultry Behavior and Management, Faculty of Veterinary Medicine, Assiut University, Assiut 71526, Egypt.

²Department of Animal and Poultry Behavior and Management, Faculty of Veterinary Medicine, Minia University, Minia, Egypt.

³Department of Physiology, Faculty of Veterinary Medicine, Assiut University, Assiut 71526, Egypt.

⁴Department of Histology, Faculty of Veterinary Medicine, Sohag University, Sohag 82524, Egypt.

ARTICLE INFO

Received: 10 September 2024

Accepted: 16 October 2024

*Correspondence:

Corresponding author: Eman A. Negm
E-mail address: Emanegm@vet.aun.edu.eg

Keywords:

Broiler chicken, Physiology, Probiotic, Health.

ABSTRACT

The present study was designed to evaluate the effects of probiotic (*Bacillus subtilis*) addition on behaviour, some health indicators and intestinal histology of broiler chickens. 210 one day old Broiler chicken was supplied by diets with probiotics at concentrations of 0 (control), 0.25 (0.25X), and 0.5 (0.5X) g/kg. Also, 4 days old, blood samples were collected for measuring liver and kidney function tests, also microbial analysis, internal morphology, and relative and absolute weight of some internal organs were done. In comparison with control, probiotics had no significant effect on broiler chickens' behavior, however, birds fed 0.25X had the highest percentage of feeding behavior among the experimental groups. Furthermore, probiotic treated groups had higher absolute weights of heart, spleen, liver, intestine and gizzard while the relative weights were not changed. Also, the *Lactobacillus* population increased while the total bacterial count decreased in probiotic-fed groups. Moreover, probiotics increased duodenum villus width and height and enhanced jejunum villus width, height, and villus height/crypt depth. In addition, it did not affect the levels of total, indirect and direct bilirubin, albumin, total protein, globulin, and albumin: globulin ratio and alkaline phosphatase regardless of its dose. The findings imply that the probiotic dietary supplement effect based on its dose and that probiotic (Clostat™) improved broilers health under normal condition and may prove to be an important way for possibly protection the health of broiler chickens.

Introduction

Live bacteria are known as probiotics that improve the gut microbial balance of the host by boosting growth efficiency (Wang *et al.*, 2021). Single or mixed cultures of live microorganisms known as probiotics are effective for balancing the intestinal flora (Ahmad, 2006; Kopacz and Phadtare, 2022). Under normal circumstances, its use speeds up the growth of helpful microorganisms rather than the growth of potentially harmful germs (Abudabos *et al.*, 2013; Ghasemi *et al.*, 2020; Joya *et al.*, 2020). Probiotics have been shown to improve growth in numerous studies (Sen *et al.*, 2012; Ghasemi-Sadabadi *et al.*, 2019), with the best feed conversion ratio standing out (Shokaiyan *et al.*, 2019; Hussein *et al.*, 2020; Joya *et al.*, 2020).

Moreover, improved gut health (Awad *et al.* 2009 and 2010), it developed broilers intestinal mucosa (Sen *et al.*, 2012; Hussein *et al.*, 2020) by raising the length of villus its ratio to the depth of crypt (Lei *et al.*, 2013; Joya *et al.*, 2020), reducing histopathological signs in intestine (Hussein *et al.*, 2020) and enhancing immune response (Yang and Sheu, 2012). Also, it raises blood albumin level (Abudabos *et al.*, 2017), total protein (Abudabos *et al.*, 2017), alkaline phosphatase (ALK) (Shokaiyan *et al.*, 2019) and glucose level (Deraz, 2018; Ghasemi-Sadabadi *et al.*, 2019).

However, some studies showed different results, which concluded that probiotics didn't affect blood physiological parameters as urea and creatinine levels (Hery *et al.*, 2020), total protein, albumin, globulin, and Albumin/globulin (A/G) ratio (Shahir *et al.*, 2014).

However, the probiotics results, and their efficacy are very variable according to strain of microorganisms used, dose of administration, method or due to bird age differences (Hong *et al.*, 2005; Aluwong *et al.*, 2013). It has a variety of effects on animal bodies and health; thus, it is impossible to generalize about how they work. More research should focus on host-probiotic interactions to better understand its mechanism of action because its effects depend on the contacts between the host

and probiotic.

So, the present research was planned to determine probiotic effects (*Bacillus subtilis*) on the behaviour patterns, performance, intestinal histomorphology, blood physiological parameters, cecal bacterial count of broiler chickens under normal condition in Egypt. Wishing to detect the economic and scientific values of probiotics as a nourishing program to enhance broilers production in normal condition as it has limited scientific bases and to determine its advantages and disadvantages to get more information about it to guide the poultry farmers either to go for application or no.

Materials and methods

Ethical approval

All precautions for using and/or dealing with laboratory birds were taken into consideration and the Ethics Committee of Faculty of Medicine, Assiut University (experiment No. 17200789).

Probiotic

A Probiotic (CLOSTAT™ HC SP Dry, Kemin, Europe, NV; Herentals, Belgium) was used in this study. It contained *Bacillus subtilis* and sodium bicarbonate.

Birds and housing

All birds handled and treated by Animal Care in Faculty of Veterinary Medicine, Assiut University, Egypt. A day age male Ross 708 broiler chicks from El Wade in Egypt, Assiut, were weighed and placed in 21 pens with equal average body weights. This was done under a controlled conditions (The Animal and Poultry Behavior and Management Research Unit,

Faculty of Veterinary Medicine, Assiut University, Egypt). At a depth of 10 cm, bedding was made of fresh, dry wood shaving. The bird management followed the recommendations of Ross, 2018.

The ambient temperature was 35°C for the first week of life, then dropped to 26°C (declined 0.5°C per day) until the experiment's end. Using thermo-hygrometer (wall-mounted) that was positioned 30 cm over the litter, actual pen humidity and temperatures were monitored twice daily (Mohammed *et al.*, 2021).

Experimental design

A conventional mixed probiotic diet (*B. subtilis* PB6, CLOSTATM; Ke-min, Europe, NV; Belgium, Herentals) fed with 0 (control), 0.25 (0.25X), and 0.5 (0.5X) g/kg was randomly assigned to the 21 floor pens in 3 treatments (7 replicates, each 10 broilers). Based on the advice of the corporation, the CLOSTAT dietary therapies' concentrations were used. The dietary therapy lasted from day 1 to 34 till they could access the marketing weight. From day 1 to 14, the birds were supplied with a starter diet, followed by grower diet from 15 to 28 days of age, and finally from 29 to 34 days they were fed a finisher diet. At all pens, water is available in clean drinkers (Mohammed *et al.*, 2019). The treatments began on the first day of age (Table 1).

Table 1. Components of base diet¹, separated by the growth phase².

Ingredient %	Starter (1-14 d)	Grower (15-28 d)	Finisher (29-34 d)
Corn ground	57.66	63.76	66.9
Soybean meal (47.5%)	35.27	29.68	26.3
Soybean oil degummed	3	3	3.52
Calcium carbonate	1.41	1.38	1.49
Phosphate monocalcium	1.42	1.02	0.82
L-Lysine	0.11	0.1	0.02
Salt plain	0.48	0.46	0.48
L-Threonine (98%)	0.06	0.04	0
DL-Methionine	0.24	0.21	0.12
Poultry turkey starter	0.35	0.35	0.35
Calculated Analysis ³			
Crude protein (%)	23.4	22.8	19.2
Metabolizable energy (kcal/kg) diet	3050	3151	3200
Calcium (%)	0.95	0.85	0.75
Available phosphorus (%)	0.5	0.44	0.36
Methionine (%)	0.66	0.59	0.53
Methionine + Cystine (%)	1.04	0.97	0.86
Lysine (%)	1.42	1.29	1.09
Threonine (%)	0.97	0.89	0.74
Na (%)	0.22	0.2	0.19

¹The ration formulation was produced according to Ross (2018), and the treatments were the regular diets supplemented with 0 (control), 0.25 (0.25X), and 0.5 (0.5X) g kg⁻¹ probiotic, respectively.

²The diets were formulated by El-salam food mill. (Assiut, Egypt).

³Provided per kilogram of diet: vitamin A, 13.233 IU; vitamin D3, 6.636 IU; vitamin E, 44.1 IU; vitamin K, 4.5 mg; thiamine, 2.21 mg; riboflavin, 6.6 mg; pantothenic acid, 24.3 mg; niacin, 88.2 mg; pyridoxine, 3.31 mg; folic acid, 1.10 mg; biotin, 0.33 mg; vitamin B12, 24.8 µg; choline, 669.8 mg; iron from ferrous sulfate, 50.1 mg; copper from copper sulfate, 7.7 mg; manganese from manganese oxide, 125.1 mg; zinc from zinc oxide, 125.1 mg; iodine from ethylene diamine dihydride, 2.10 mg; selenium from sodium selenite, 0.30 mg.

Data collection

Behavioral observations

For observation, five broiler chicks each pen (total 35 per treatment) were chosen randomly and signed with a marker. Data are presented as the proportion of each behavioral frequency (Mahmoud *et al.*, 2015 &

2017; Mohammed *et al.*, 2018).

From day 15 to day 34, behaviour was observed three times per week (Monday: Wednesday) from 10:00 to 11:00 and 14:00 to 15:00. All observations were made by two qualified people (good trained in viewing and analyzing chickens' behaviour using ethogram and they were unaware about the treatment), and they were standing during all data collecting times, away from pens by 1.5m. All marked birds in one pen (i.e., seven pens) were observed for 6 minutes on their behaviour. The scientist walked to another pen after sampling one pen and repeated the behavioural observation. In total, the behavior was scanned 12 times each day (i.e., six times per hour for each pen).

The percentage of each behavioural frequency is shown in the data as "the possible number of scans out of the total number" (Mahmoud *et al.*, 2015; Mohammed *et al.*, 2018).

Behavioral ethogram was applied as shown by Mahmoud *et al.* (2017):

Physiological Indicators

Blood samples

Blood parameters were estimated in the laboratory of Animal Hygiene Department, Faculty of Vet. Medicine, Assiut University. Blood parameters were estimated according to the recommendations of (Mahmoud, 2010). At 34 days old, 7 birds were randomly selected from each group to measure liver and kidney function tests. Following the traditional Islamic Halal Technique (Shahdan *et al.*, 2016), the birds were killed by cutting their jugular veins, letting them bleed for 120 seconds, and then semi-scalding them for 30 seconds at 54°C before manually plucking them. The birds were physically dissected, and the bodies were cleaned then left to drain for ten minutes. During the bird's exsanguinations, three mL of blood were collected from each bird in a plain tube. The tubes were first held at ambient temperature for 30 minutes, then placed in the refrigerated for 60 to 90 minutes, and lastly centrifuged at 3000 rpm for 10 minutes, with the separated serum being transferred using a micropipette to another Epindoorf's tube. Sera were stored at -20°C until examination with a commercial kit in accordance with the manufacturer's instructions.

Chemical parameters

Liver functions tests

Serum Alkaline phosphatases (Alp), total protein, globulin albumin, albumin / globulin (A/G) ratio, bilirubin (direct, indirect, and total). Total serum proteins, albumin, total bilirubin, and alkaline phosphatase were estimated by spectrophotometer Digital-VIS/ultraviolet (Cecil instruments, England, Cambridge, Series NO. 52.232).

ALP, Total serum proteins and albumin were detected by using a commercial colorimetric kit made by an Egyptian biotechnology company, Cairo, Egypt. Serum bilirubin was assayed by a quantitative determination of bilirubin IVD using a commercial kit made by diamond company, USA. Serum globulins (g/dl) and Albumin/ Globulin ratio (A/G) were determined mathematically (Elbahi, 2003).

Kidney function tests

Serum urea and creatinine was measured using a professional colorimetric kit made by the Diamond Company in the United States.

Internal organs actual and relative weight

At 34 days old, 7 chicks/treatment (i.e., 1 chick was chosen) were used. After removing the viscera, the intestine, heart, liver, spleen, and gizzard were taken, weighed and then calculated as a percentage of the

life body weight (Dehghani-Tafti and Jahanian, 2016).

Gastro-intestinal character

The same sampled birds were used for intestinal microbiological and morphometric analyses.

Microbial analysis

Following euthanasia, chicken cecal contents (1 g) were taken to count the lactobacilli and other microorganisms. Until analysis, samples were kept in cryovials at -80 °C.

A modified version of the previously reported approach (Sieuwerts *et al.*, 2008) for miniature plating of microorganisms was used. The method for microorganism miniature plating that was previously reported (Sieuwerts *et al.*, 2008) was modified. In a nutshell, the contents of the gut were serially (10-fold) diluted in peptone water (Neogen Corporation, MI, Lansing). For various gut microbial groups, samples (10uL) were plated on several agar types: For total lactobacilli, Rogosa agar (Fisher Scientific/Becton, Dickinson Co., Sparks, MD 38800) was used; for the total amount of bacteria, plate count agar (bio-lab Co., 14 St., El-hegaz Street, Heliopolis, Cairo, 11311) was used. The first agar was kept for 24 hours in an incubator at 37°C, whereas the second was incubated for 48 hours at 35°C. Colonies enumerated after incubation and documented as colony units per gram of sample in a spreadsheet.

Intestinal morphometry

Before gathering the tissue fragments, the digestive tract was removed. Duodenum, Jejunum and Ileum were dissected (Akbarian *et al.*, 2013; Abdel-Mohsein *et al.*, 2014). At the halfway point of each segment, tissue samples (2 cm) were collected, preserved in a 4% formalin solution, and then prepared for examination. Each intestinal sample was cut into 0.5 cm segment, dehydrated in a graduated absolute ethanol (50%, 70%, 80%, 90%, and 100%), embedded in xylene (Sub-X, Surgipath Medical Industries, Richmond, IL) and finally wax paraffin were added to the sample (Polysciences, Warrington, PA). Four cross-sections of each cut into 7 m thickness, put on slides, stained with hematoxylin stain and eosin (Sigma) and examined by an OPTIKA microscope (Italy) fitted with a digital OPTIKA. The OPTIKA PROVIEW software determined the crypt depth, villus width and height of the jejunum and duodenum. The villus height/crypt depth ratio was determined. The appearance of normal lamina propria served as the villus selection criterion. To reduce sectioning variations, the crypt-villus units (total 16/segment) were randomly selected from four locations in cross section and four sections per intestine sample each bird. The crypt depth, villus width, height and villus height/crypt depth ratio of the jejunum and duodenum each chicken were averaged within the pen.

Statistical analysis

Seven pens in each treatment were used as a randomized designed experiment with the dietary supplement acting as the fixed effect. Data evaluated by One-way ANOVA (SAS Institute Inc., NC, Cary). When a significant difference was found and means needed to be compared, using Tukey-Kramer test. Results were recorded in mean \pm SEM showing difference set $P \leq 0.05$.

Results

The overall relationships between probiotic supplementations and behavioral activities are cleared in Table 2. Compared to control, the different treatments of probiotics show no significant changes on broiler chickens' behavior ($P > 0.05$), expect the 0.25X birds had the highest percentage of feeding behavior in comparison with control ($P = 0.0370$).

The means of both the relative weights of the liver, heart, spleen, intestine, and gizzard were shown in Figure 1. In comparison to the control, the relative weights of liver, heart, spleen, intestine and gizzard showed no difference in relation to different concentrations of the probiotic ($P = 0.8721, 0.926, 0.6390, 0.4306, 0.3808$, respectively).

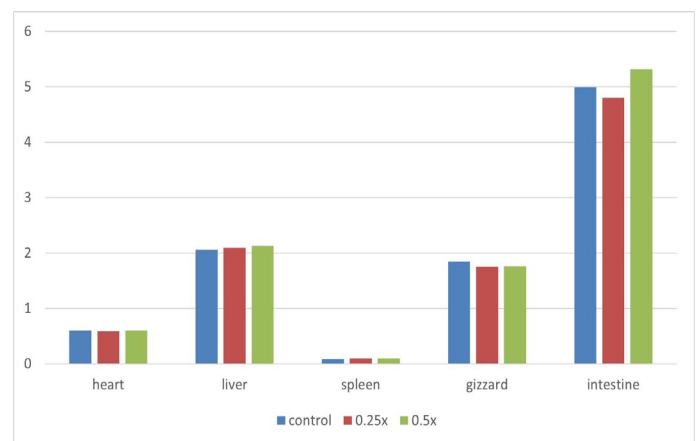


Figure 1. Effect of probiotic (mg/kg diet) on relative weight (%) of heart, liver, spleen, gizzard, and intestine in broilers (d 34). Means \pm SE, does not differ significantly ($P > 0.05$).

The overall relationships between the probiotic treatments and cecal bacterial counts (cfu / g) in broiler chickens are listed in Table 3. In comparison to the control, *Lactobacillus* population increased ($P = 0.0001$) in probiotic-fed broiler chickens regardless of dose. In contrast, the total bacterial count was decreased in probiotic-fed broiler chicken ($P = 0.0006$).

Compared to controls, the probiotic supplementations raised villus height and width of the duodenum ($P = 0.0001$). However, the differences had disappeared in crypt depth and villus height: crypt depth ratio of

Table 2. Effect of Probiotic (mg/kg diet) on behavior activities (%) of broilers.

Treatments	Control 0.0X	0.25X	0.5X	P value
Feeding (%)	7.20 \pm 0.76	10.20 \pm 0.76	7.80 \pm 0.76	0.04
Drinking (%)	4.80 \pm 0.41	5.60 \pm 0.41	5.00 \pm 0.41	0.38
Walking (%)	1.20 \pm 0.22	1.00 \pm 0.22	1.00 \pm 0.22	0.76
Standing (%)	1.60 \pm 0.37	2.40 \pm 0.37	1.00 \pm 0.37	0.06
Resting (%)	72.60 \pm 1.11	71.00 \pm 1.11	73.2 \pm 1.11	0.35
Wing preening (%)	4.20 \pm 0.41	4.00 \pm 0.41	4.6 \pm 0.41	0.59
Wing & leg stretching (%)	5.80 \pm 0.53	4.40 \pm 0.53	5.80 \pm 0.53	0.14
Body shacking (%)	0.60 \pm 0.26	1.00 \pm 0.26	0.20 \pm 0.26	0.13
Dust bathing (%)	0.20 \pm 0.12	0.00 \pm 0.12	0.00 \pm 0.12	0.40
Wall pecking (%)	0.60 \pm 0.18	0.20 \pm 0.18	0.00 \pm 0.18	0.10

^a and ^b Means \pm SE with different superscripts in the same row differ significantly ($p < 0.05$).

duodenum between all the treatments ($P = 0.1365, 0.4745$ respectively) as listed in Table 4.

Table 3. Effect of probiotic (mg/kg diet) on cecal bacterial count (\log_{10} cfu / g) of broilers (d 34):

Treatments	<i>Lactobacillus</i>	Total bacterial count
Control 0.0X	11.73±0.095 ^b	10.51±0.078 ^a
0.25X	12.66±0.095 ^a	10.03±0.078 ^b
0.5X	12.93±0.095 ^a	10.07±0.078 ^b
P value	0.00	0.00

^a and ^b Means ± SE in the same column with different superscripts differ significantly ($P < 0.05$).

Villus height and width, depth of crypts and villus height/crypt depth ratio in the jejunum are presented in Table 4. Compared to controls, villus width was increased in the probiotic supplementation with dose effect, 0.5X had the highest in-creased ($P = 0.0001$). At the same time, villus height was enhanced in the treated chicks in comparison with controls ($P = 0.0001$). Villus height/crypt depth ratio was also raised in the probiotic treated birds regardless of its dose in comparison with controls ($P = 0.0003$). At the same time, probiotic supplementation did not affect the depth of the crypt regardless of its dose ($P = 0.5372$).

It shows no significant effect on the levels of total, direct and indirect bilirubin regardless of its dose ($P = 0.7124, 0.0968, 0.3043$ respectively) as cleared in Table 5.

Probiotic treatment did not affect globulin, albumin, total protein, and albumin: globulin ratio and, alkaline phosphatase ($P = 0.4917, 0.1039, 0.206, 0.6255, \text{ and } 0.179$ respectively). Also, it did not affect the urea and creatinine levels ($P = 0.8866, 0.8780$) as presented in Table 5.

Discussion

In the current research, the different probiotics doses didn't show any significant effect on broiler behavior compared to control group. However, 0.25X birds had the highest percentage of feeding behavior in comparison with control and 0.5X birds ($P = 0.0370$). These results supported the report made by El Iraqi and Fayed (2012) who found that, 1g of dry yeast as probiotic supplementation in the broiler diet increased feeding behaviour (frequency and duration) because of probiotics stimulate appetite of the host while there was no significant effect on leg and wing stretching behaviour, resting, drinking, ground scratching, body shacking behaviour. Similarly, Abdel-Azeem (2013) revealed that, probiotics (Eco-biol®, *Bacillus amyloliquefaciens* spores and a carrier in the form milk serum with concentration 1×10^{10} CFU/g) supplementation in drinking water to turkey poults increased feeding behaviour (frequency and duration), but had no effect on drinking behaviour, sleep, and rest behaviour (sleeping, lying down), dust bathing, standing, walking, preening, running, picking, and scratching behaviour. These results can be explained as bacterial microorganisms and the brain interact with each other, so bacteria that is found in the stomach can affect neuronal function changing the mood and behaviour.

In contrast, El Iraqi and Fayed (2012) recorded that, dry yeast and Rayeb milk as *Lactobacillus* spp. probiotic significantly decreased (duration and frequency) of resting, feeding, drinking behavior and dust bathing activities. This difference may be due to the changes in environment and chicken types used in each study.

The relative weights of gizzard, heart, spleen, liver and intestine weights were not changed by the probiotic supplementation regardless of its dose in our study. Same were reported by Deraz *et al.*, (2019) who recorded that, dietary supplementation of probiotics lactic acid bacteria isolated from *Lactobacillus* show no significant effect on adrenal gland,

Table 4. Effect of probiotic (mg/kg diet) on width, height of villus, depth of crypt and ratio in duodenum (D.) and jejunum (J.) of broilers (d 34).

Treatments	Control 0.0X	0.25X	0.5X	P value
Width of V. D. (μm)	142.60±6.75 ^b	211.20±6.75 ^a	196.70±6.75 ^a	0.00
Height of V. D. (μm)	773.80±58.2 ^b	1189.80±58.2 ^a	1166.10±58.2 ^a	0.00
Depth of crypt D. (μm)	201.30±20.86	241.80±20.86	262.70±20.86	0.14
Ratio of villus / crypt D.	4.07±0.59	5.01±0.59	4.95±0.59	0.47
Width of V. J. (μm)	91.27±6.75 ^c	161.70±6.75 ^b	212.85±6.75 ^a	0.00
Height of V. J. (μm)	632.20±37.2 ^b	1144.90±37.2 ^a	1240.20±37.2 ^a	0.00
depth of crypt J. (μm)	354.40±28.4	354.18±28.4	314.85±28.4	0.54
Ratio of villus: crypt J.	1.90±0.32 ^b	3.40±0.32 ^a	4.10±0.32 ^a	0.00

^{a, b} and ^c Means ± SE in the same row with different superscripts differ significantly ($P < 0.05$).

Table 5. Effect of probiotic (mg/kg diet) on liver function test (total, direct and indirect bilirubin, total protein, albumin, globulin, A/G ratio and alkaline phosphatase) and on kidney function test (urea and creatinine) of broilers (d 34).

Treatments	Control 0.0X	0.25X	0.5X	P value
Total bilirubin (g/dl)	0.323±0.032	0.33±0.03	0.358±0.032	0.71
Direct bilirubin (g/dl)	0.13±0.0173	0.09±0.017	0.147±0.0173	0.10
Indirect bilirubin (g/dl)	0.19±0.0203	0.24±0.020	0.2108±0.0203	0.30
Total protein (mg/dl)	1.73±0.0975	1.78±0.09	1.97±0.0975	0.21
Albumin (mg/dl)	1.48±0.066	1.45±0.07	1.64±0.066	0.10
Globulin (mg/dl)	0.39±0.065	0.29±0.06	0.330±0.055	0.49
A/G ratio	4.58±1.595	6.69±1.456	5.57±1.348	0.63
ALK (alkaline phosphatase)	1200.0±256.2	1903.60±256.20	1597.2±256.2	0.18
Urea (mg/dl)	0.25±0.0215	0.24±0.022	0.23±0.0215	0.89
Creatinine (mg/dl)	0.73±0.0398	0.700±0.039	0.725±0.0398	0.88

Means ± SE in the same row does not differ significantly ($P > 0.05$).

intestine, kidney, gizzard, heart, liver relative weight of broilers. Contrary, Sugiharto *et al.*, (2018) stated that dietary multistrain probiotic (*Bacillus* probiotics) reduced ($p \leq 0.05$) relative weight of heart but increase that of pancreas, ileum, and spleen (Karimi Torshizi *et al.*, 2010; Chen *et al.*, 2013).

The increased internal organ weight in a probiotic fed birds might be attributed to the enhanced microbial or digestive enzymatic activity (Habibi *et al.*, 2013) or because of the presence of beneficial bacteria which improved body weight and feed intake that may be due to the increase in the actual weight of liver, heart, intestine, and gizzard weight (Seifi *et al.*, 2013; Shokaiyan *et al.*, 2019). Also, it might be attributed to histopathological alternations in structure of crypt depth and villus height (Sohail *et al.*, 2012), or an elevation in mucus layer thickness (Tsirtsikos *et al.*, 2012). The improved spleen weight may be because of higher production of antibody (Kabir *et al.*, 2004).

In the current research, probiotic supplementation did not disturb the levels of total, direct and indirect bilirubin regardless of its dose ($P = 0.7124, 0.0968$ and 0.3043 respectively). Similarly, Bityutskyy *et al.* (2019) recorded that dietary mix of *Lactobacillus casei* IMV B- 7280, *Bifidobacterium animalis* VKB and *Bifidobacterium animalis* VKL (Probiolact) didn't change total bilirubin levels in quail raised under normal condition. He explained that there are no significant effects in total bilirubin after dietary probiotic supplementations means that the probiotic has no bad effect on the liver. In contrast goslings reared under normal condition feeding with *Paenibacillus*-based probiotic (Bacispecin) increased blood bilirubin levels (Khaziahmetov *et al.*, 2018).

Moreover, in our research, treatment did not show any effect on globulin, total protein, albumin and albumin: globulin ratio ($P = 0.206, 0.1039, 0.4917,$ and 0.6255 respectively). Similarly, Shahir *et al.* (2014) found that supplementation of 0.1% probiotic (*Saccharomyces cerevisiae* 47 (Biosof®) in food had no effect on albumin, total protein and albumin/globulin ratio of broiler chickens raised under normal conditions. Otherwise, Gong *et al.* (2018) stated that, feed with probiotic (*Bacillus s. natto*, *Bacillus licheniformis* and *Bacillus cereus*) had a significant elevation in albumin, total protein, globulin, and A/G ratio in broilers blood raised on normal situation at 42 days. While, Pietras (2001) stated that, using two types of probiotic bacteria (*Lactobacillus* and *Streptococcus faecium*) in food from 1 to 21 days decreased total protein that may indicate kidney, liver or bleeding disorders, while elevated total protein may indicate infections, inflammation, or bone marrow disorders so no change in the levels of albumin and total protein indicates normal metabolic status and health (Mahmoud *et al.*, 2016) which usually are used as an indicator to humoral immunity.

An enzyme known as alkaline phosphatase (ALP) has been found in many bodily tissues. It is primarily found in the liver and the remaining amounts are found in the bones of healthy animals. Therefore, liver illness, gallbladder disease, bile duct obstruction, or bone problems are the main causes of elevated blood ALP levels. In the present research, alkaline phosphatase level was also not changed by probiotic supplementation ($P = 0.179$) regardless of its dose. These results supported the report by Abd-El-Rahman *et al.* (2012) who found that, Revitylyte-Plus™ (a mix of *Enterococcus faecium*, *Lactobacillus plantarum*, *Lactobacillus acidophilus* and *Lactobacillus casei*) and Bactocell® (*Pediococcus acidilactici*) as probiotic supplementation in the broiler diet under normal condition had no significant effect on the level of blood alkaline phosphatase (ALP) that may be attributed to the normal metabolic status and health.

On contrary, Shokaiyan *et al.* (2019) recorded that dietary probiotic of (*Bacillus subtilis* DSMZ) Gallipro® increased alkaline phosphatase levels in broiler chickens' blood which grown under normal condition. Meanwhile, Krauze *et al.* (2020) stated that dietary broiler fed diet with probiotics (*Bacillus* and *Enteriococcus faecium*) decreased the level of ALP in blood.

Our results reflected that urea and creatinine blood levels ($p = 0.8866, 0.8780$) in broiler chicken didn't change by probiotic. Same results were in agree with Hery *et al.* (2020), who found that, probiotic addition (*Candida*

ethanolica, *Monascus fumeus*, and *Bacillus subtilis*) at three level 0.5, 0.25, 0.75 % had no effect on plasma creatinine and blood urea nitrogen concentration in broiler chickens in comparison to the control group.

In the current study, compared to controls, the count *Lactobacillus* population increased ($P = 0.0001$) in probiotic broiler chickens regardless of dose. In contrast, the total bacterial count was decreased in probiotic-fed broilers compared with control birds ($P = 0.0006$). Similarly, Krauze *et al.* (2020) and Park *et al.* (2018) stated that, addition of *Bacillus* as a probiotic to broiler chickens improved intestinal microbiota, by decreasing the number of total bacteria count while increasing the lactobacilli count. In contrast, Molnár *et al.* (2011) found that the number of *Lactobacillus* spp. in ileum or caecum of broiler chickens raised on normal conditions wasn't affected by the greater inclusion rate of *Bacillus subtilis*. The presence of probiotics in the diet increased populations of good bacteria, as bifidobacterium and *Lactobacillus*, leading to rapid consuming of oxygen with decreasing in pH, which prefers lactobacilli while inhibits *Escherichia coli* (*E. coli*) due to more volatile fatty acids and lactic acid are produced. Also, the addition of bacillus fights with potential enteric pathogenic microorganism for nutrients and binding sites on enterocytes. So, gastrointestinal tract environment becomes unsuitable for bad pathogenic microorganism proliferation like coliforms, *Salmonella* and *Escherichia coli* (*E. coli*) (Khaliq and Ebrahimnezhad., 2016; Al-Khalaifa *et al.*, 2019). Also, this inhibition may be because of the release of numerous antimicrobial components, like hydrogen peroxide, organic acids, and bacteriocins (Park *et al.*, 2018; Krauze *et al.*, 2020).

In our current study, dietary probiotic-fed influenced small intestine histomorphological structure in broiler chickens as it considered the most important markers of gut health because villus height and crypt depth are used to determine gut efficiency. Our study demonstrated changes in intestinal architecture in terms, increased villus width and height of the duodenum, enhanced villus height, width, and villus height: crypt depth of broiler chicken jejunum, while the probiotic had no effects on duodenum and jejunum crypt depth. In the duodenum, the probiotic supplementation increased villus width and height ($P = 0.0001$). These finding agreed with Dobrowolski *et al.* (2019) who revealed that, probiotic-fed (*Lactobacillus casei* LOCK 0915, *Lactococcus lactis* IBB500, *Carnobacterium diver-gens*S1, *Saccharomyces cerevisiae* LOCK 014 and *Lactobacillus plantarum* LOCK 0862) to female turkey reared under normal condition increased the duodenum villus width and height. In contrast, Abudabos *et al.* (2013) said that dietary fed by *Bacillus subtilis* (Clostat™) as a probiotic had no effect on villus width or height of broiler duodenum grown under normal habitat.

Moreover, in this research, the differences have disappeared in duodenum villus height: crypt depth ratio and crypt depth between all treatments ($P = 0.1365, 0.4745$ respectively) when compared to the controls. This result supported the report published by Allahdo *et al.* (2018) who recorded that, *Lactobacillus*-Bactocell administration (*Pediococcus acidilactici* MA 18/5M) probiotic didn't affect villus height: crypt depth ratio of the broiler chicken's duodenum under normal condition. Contradictory, Elhassan *et al.* (2019) found that *Bacillus subtilis* as probiotic treatment to broiler chicken diet increased villus height: crypt depth ratio and significantly declined duodenum crypt depth after 42 d of experiment.

Probiotic dietary administration affected intestinal morphometry in the jejunum by increasing villus width with a dose effect, 0.5X have the greatest increase ($P = 0.0001$). At the same time, villus height was increased in the probiotic fed birds in comparison with the controls ($P = 0.0001$). Similarly, were found by Bai *et al.* (2018) who said that dietary *Bacillus subtilis* supplementation enhanced the jejunum villus width and height of broiler raised on normal condition. In contrast, Abudabos *et al.* (2013) recorded that, *Bacillus subtilis* probiotic (Clostat™) didn't show effect on jejunal height or villus width of broiler chickens exposed to *C. perfringens* infection.

In addition, in the current research the ratio of villus height/crypt depth as elevated in the probiotic fed birds regardless of its dose in com-

parison with the controls ($P = 0.0003$). At the same time, probiotic supplementation did not affect the crypt depth regardless of its dose ($P = 0.5372$). This result is in line with Oladokun *et al.* (2021) who found that, dietary fed with *Bacillus subtilis* as ovo probiotic didn't has effect on villus height/ crypt depth ratio but increased total thickness of jejunum mucosa in broiler chickens reared under normal condition

Conclusion

The effects of the *Bacillus subtilis* probiotic as a growth promoter enhance the behavior activities, internal organs weight and total bacterial count. The current preliminary study suggests that dietary probiotic supplementation may improve the animal's health.

Conflict of interest

The authors have no conflict of interest to declare.

References

- Abdel-Azeem, M.N., 2013. Do probiotics affect the behavior of turkey poults? *Journal of Veterinary Medicine and Animal Health* 5, 144-148.
- Abdel-Mohsein, H.S., Mahmoud, M.M., Mahmoud, U.T., 2014. Influence of propolis on intestinal microflora of ross broilers exposed to hot environment. *Advances in Animal and Veterinary Sciences* 2, 204-211.
- Abd-El-Rahman, A.H., Kamel, H.H., Ahmed, W.M., Mogoda, O.S.H., Mohamed, A.H., 2012. Effect of Bactocell® and Revitylite-Plus™ as probiotic food supplements on the growth performance, hematological, biochemical parameters and humoral immune response of broiler chickens. *World Applied Sciences Journal* 18, 305-316.
- Abudabos, A.M., Alyemni, A.H., AlMarshad, M.B.A., 2013. *Bacillus subtilis* PB6 Based-probiotic (CloSTATM) improves intestinal morphological and microbiological status of broiler chickens under clostridium perfringens challenge. *International Journal of Agriculture and Biology* 15, 978-982.
- Abudabos, A.M., Alyemni, A.H., Dafalla, Y.M., Al-Owaimer, A.N., 2017. Effect of organic acid blend and *Bacillus subtilis* on growth, blood metabolites and antioxidant status in finishing broilers challenged with clostridium perfringens. *Journal of Animal and Plant Sciences* 27, 1101-1107.
- Ahmad, I., 2006. Effect of probiotics on broilers performance. *International Journal of Poultry Science* 5, 593-597.
- Akbarian, A., Golian, A., Kermanshahi, H., Farhoosh, R., Raji, A.R., De Smet, S., Michiels, J., 2013. Growth performance and gut health parameters of finishing broilers supplemented with plant extracts and exposed to daily increased temperature. *Spanish Journal of Agricultural Research* 11, 109-119.
- Al-Khalifa, H., Al-Nasser, A., Al-Surayee, T., Al-Kandari, S., Al-Enzi, N., Al-Sharrah, T., Ragheb, G., Al-Qalaf, S., Mohammed, A., 2019. Effect of dietary probiotics and prebiotics on the performance of broiler chickens. *Poultry Science* 98, 4465-4479.
- Allahdo, P., Ghodrati, J., Zarghi, H., Saadatfar, Z., Kermanshahi, H., Edalati Dovom, M.R., 2018. Effect of probiotic and vinegar on growth performance, meat yields, immune responses, and small intestine morphology of broiler chickens. *Italian Journal of Animal Science* 17, 675-685.
- Aluwong, T., Kawu, M., Raji, M., Dzenda, T., Govwang, F., Sinkalu, V.J., Ayo, J., 2013. Effect of yeast probiotic on growth, antioxidant enzyme activities and malondialdehyde concentration of broiler chickens. *Antioxidants* 2, 326-339.
- Awad, W.A., Ghareeb, K., Böhm, J., 2010. Effect of addition of a probiotic micro-organism to broiler diet on intestinal mucosal architecture and electrophysiological parameters. *Journal of Animal Physiology and Animal Nutrition* 94, 486-494.
- Bai, K., Feng, C., Jiang, L., Zhang, L., Zhang, J., Zhang, L., Wang, T., 2018. Dietary effects of *Bacillus subtilis* fmbj on growth performance, small intestinal morphology, and its antioxidant capacity of broilers. *Poultry Science* 97, 2312-2321.
- Bityutskyy, V., Tsekhmistrenko, S., Tsekhmistrenko, O., Melnychenko, O., Khar-chyshyn, V., 2019. Effects of different dietary selenium sources including probiotics mixture on growth performance, feed utilization and serum biochemical profile of quails. In: Nadykto, V. (eds) *Modern Development Paths of Agricultural Production*. Springer, Cham. https://doi.org/10.1007/978-3-030-14918-5_61
- Chen, W., Wang, J.P., Yan, L., Huang, Y., 2013. Evaluation of probiotics in diets with different nutrient densities on growth performance, blood characteristics, relative organ weight and breast meat characteristics in broilers. *British Poultry Science* 54, 635-641.
- Dehghani-Tafti, N., Jahanian, R., 2016. Effect of supplemental organic acids on performance, carcass characteristics, and serum biochemical metabolites in broilers fed diets containing different crude protein levels. *Animal Feed Science and Technology* 211, 109-116.
- Deraz, S.F., 2018. Synergetic effects of multispecies probiotic supplementation on certain blood parameters and serum biochemical profile of broiler chickens. *Journal of Animal Health and Production* 6, 27-34.
- Deraz, S.F., Elkomy, A.E., Khalil, A.A., 2019. Assessment of probiotic-supplementation on growth performance, lipid peroxidation, antioxidant capacity, and cecal microflora in broiler chickens. *Journal of Applied Pharmaceutical Science* 9, 30-39.
- Dobrowolski, P., Tomaszewska, E., Klebaniuk, R., Tomczyk-Warunek, A., Szymańczyk, S., Donaldson, J., Świątlicka I., Mielnik-Błaszczak, M., Kuc, D., Muszyński, A., 2019. Structural changes in the small intestine of female turkeys receiving a probiotic preparation are dose and region dependent. *Animal* 13, 2773-2781.
- El Iraqi, G.K., Fayed, R.H., 2012. Effect of yeast as feed supplement on behavioural and productive performance of broiler chickens. *Life Science Journal* 9, 4026-4031.
- Elhassan, M.M.O., Ali, A.M., Blanch, A., Kehlet, A.B., Madekurozwa, M.C., 2019. Morphological responses of the small intestine of broiler chicks to dietary supplementation with a probiotic, acidifiers, and their combination. *Journal of Applied Poultry Research* 28, 108-117.
- Ghasemi, R., Sedghi, M., Mahdavi, A.H., 2020. Evaluation of probiotic, prebiotic, and synbiotic on performance, immune responses, and gastrointestinal health of broiler chickens. *Poultry Science Journal* 8, 175-188.
- Ghasemi-Sadabadi, M., Ebrahimnezhad, Y., Shaddel-Tili, A., Bannapour-Ghaffari, V., Kozehgari, H., Didehvar, M., 2019. The effects of fermented milk products (kefir and yogurt) and probiotic on performance, carcass characteristics, blood parameters, and gut microbial population in broiler chickens. *Archives Animal Breeding* 62, 361-374.
- Gong, L., Wang, B., Mei, X., Xu, H., Qin, Y., Li, W., Zhou, Y., 2018. Effects of three probiotic *Bacillus* on growth performance, digestive enzyme activities, antioxidative capacity, serum immunity, and biochemical parameters in broilers. *Animal Science Journal* 89, 1561-1571.
- Habibi, S., Khojasteh, S., Jafari, M., 2013. The Effect of bactoell and protexin probiotics on performance and carcass characteristics of broiler chickens. *J. Nov. Appl. Sci.* 2, 565-570.
- Hery, S., Rifqi, I., Novi, M., 2020. Effects of probiotic supplementation to diets on blood urea nitrogen and plasma creatinine in broiler chicken. *J. Lucrări Științifice-Universitatea de Științe Agricole și Medicină Veterinară* 73, 23-27.
- Hong, H.A., Duc, L.H., Cutting, S.M., 2005. The use of bacterial spore formers as probiotics. *FEMS Microbiol Rev.* 29, 813-835.
- Hussein, E.O.S., Ahmed, S.H., Abudabos, A.M., Aljumaah, M.R., Alkhulaifi, M.M., Nassan, M.A., Suliman, G.M., Naiel, M.A.E., Swelum, A.A., 2020. Effect of antibiotic, phytobiotic and probiotic supplementation on growth, blood indices and intestine health in broiler chicks challenged with clostridium perfringens. *Animals* 10, 507.
- Joya, M., Ashayerizadeh, O., Dastar, B., 2020. Effects of spirulina (*arthrospira*) platensis and *Bacillus subtilis* pb6 on growth performance, intestinal microbiota and morphology, and serum parameters in broiler chickens. *Animal Production Science* 61, 390-398.
- Kabir, S.M.L., Rahman, M.M., Rahman, M.B., Rahman, M.M., Ahmed, S.U., 2004. The dynamics of probiotics on growth performance and immune response in broilers. *International Journal of Poultry Science* 3, 361-364.
- Karimi Torshizi, M.A.K., Moghaddam, A.R.R., Rahimi, S., Mojjani, N., Torshizi, M.A.K., Moghaddam, A.R.R., Rahimi, S., Mojjani, N., 2010. Assessing the effect of administering probiotics in water or as a feed supplement on broiler performance and immune response. *British Poultry Science* 51, 178-184.
- Khalqi, M., Ebrahimnezhad, Y., 2016. The effects of probiotic Yeasture® using at different rearing periods on performance, intestinal microbial population and carcass traits in broiler chickens. *Veterinary Science Development*. 6.
- Khaziahmetov, F., Khabirov, A., Avzalov, R., Tsalalova, G., Tagirov, K., Giniyatullin, S., Andreeva, A., Gafarova, F., Gafarov, F., 2018. Effects of *Paenibacillus*-based probiotic (*Bacispecin*) on growth performance, gut microflora and hematology indices in goslings. *Journal of Engineering and Applied Sciences* 13, 6541-6545.
- Kopacz, K., Phadtare, S., 2022. Probiotics for the Prevention of Antibiotic-Associated Diarrhea. *Healthcare (Basel)* 10, 1450.
- Krauze, M., Abramowicz, K., Ognik, K., 2020. The effect of addition of probiotic bacteria (*Bacillus subtilis* or *Enterococcus faecium*) or Phytobiotic containing Cinnamon oil to drinking water on the health and performance of broiler chickens. *Annals of Animal Science* 20, 191-205.
- Lei, K., Li, Y.L., Yu, D.Y., Rajput, I.R., Li, W.F., 2013. Influence of dietary inclusion of *Bacillus licheniformis* on laying performance, egg quality, antioxidant enzyme activities, and intestinal barrier function of laying hens. *Poultry Science* 92, 2389-2395.
- Mahmoud, H.E., Daichi, I., Tarek, A.E., Akira, O., 2016. Effects of dietary nano-selenium supplementation on growth performance, antioxidative status, and immunity in broiler chickens under thermoneutral and high ambient temperature conditions. *The Journal of Poultry Science* 53, 274-283.
- Mahmoud, U., 2010. Studies on some behavioral patterns of quails with special reference to effect of heat stress on behaviours, performance and some blood parameters. Master Thesis. Faculty of Veterinary Medicine, Assiut University, Egypt.
- Mahmoud, U.T., Abdel-Rahman, M.A.M., Darwish, M.H.A., Applegate, T.J., Cheng, H.W., 2015. Behavioral changes and feathering score in heat stressed broiler chickens fed diets containing different levels of propolis. *Applied Animal Behaviour Science* 166, 98-105.
- Mahmoud, U.T., Khalil, N.S.A., Elsayed, M.S.A., 2017. Behavioral and physiological effects of mannan-oligosaccharide and β -glucan prebiotic combination on heat stressed broiler chickens. *Journal of Advanced Veterinary Research* 7, 81-86.
- Mohammed, A.A., Jacobs, J.A., Murugesan, G.R., Cheng, H.W., 2018. Animal well-being and behavior: Effect of dietary synbiotic supplement on behavioral patterns and growth performance of broiler chickens reared under heat stress. *Poultry Science* 97, 1101-1108.
- Mohammed, A.A., Zaki, R.S., Negm, E.A., Mahmoud, M.A., Cheng, H.W. 2021. Effects of dietary supplementation of a probiotic (*Bacillus subtilis*) on bone mass and meat quality of broiler chickens. *Poultry Science* 100, 100906.
- Mohammed, A.A., Jiang, S., Jacobs, J.A., Cheng, H.W., 2019. Effect of a synbiotic supplement on cecal microbial ecology, antioxidant status, and immune response of broiler chickens reared under heat stress. *Poultry Science* 98, 4408-4415.
- Molnár, A.K., Podmaniczky, B., Kürti, P., Tenk, I., Glávits, R., Virág, G., Szabó, Z., 2011. Effect of different concentrations of *Bacillus subtilis* on growth performance, carcass quality, gut microflora and immune response of broiler chickens. *British Poultry Science* 52, 658-665.
- Elbahi, N.M.A., 2003. A study of some physiological, productive and reproductive parameters of Japanese quail under stress condition. PhD. Thesis Department

- of poultry production. Faculty of Agriculture. El-Fayoum. Cairo University, Egypt.
- Oladokun, S., Koehler, A., MacIsaac, J., Ibeagha-Awemu, E.M., Adewole, D.I., 2021. *Bacillus subtilis* delivery route: effect on growth performance, intestinal morphology, cecal short-chain fatty acid concentration, and cecal microbiota in broiler chickens. *Poultry Science* 100, 100809.
- Park, J.H., Yun, H.M., Kim, I.H., 2018. The effect of dietary *Bacillus subtilis* supplementation on the growth performance, blood profile, nutrient retention, and caecal microflora in broiler chickens. *Journal of Applied Animal Research* 46, 868–872.
- Pietras, M., 2001. The effect of probiotics on selected blood and meat parameters of broiler chickens. *Journal of Animal and Feed Sciences* 10, 297–302.
- Aviagen, 2018. Ross Broiler Management Handbook. Retrieved from 2018. Available 336 from: https://en.aviagen.com/assets/Tech_Center/Ross_Broiler/Ross337_BroilerHandbook2018-EN.pdf.
- Seifi, S., Shirzad, M.R., Habibi, H., 2013. Effects of probiotic yoghurt and prebiotic utilization on performance and some haematological parameters in broiler chickens. *Acta Scientiae Veterinari*. 41, 1–6.
- Sen, S., Ingale, S.L., Kim, Y.W., Kim, J.S., Kim, K.H., Lohakare, J.D., Kim, E.K., Kim, H.S., Ryu, M.H., Kwon, I.K., Chae, B.J., 2012. Effect of supplementation of *Bacillus subtilis* LS 1-2 to broiler diets on growth performance, nutrient retention, caecal microbiology and small intestinal morphology. *Research in Veterinary Science* 93, 264–268.
- Shahdan, I.A., Regenstein, J.M., Shahabuddin, A.S.M., Rahman, M.T., 2016. Developing control points for halal slaughtering of poultry. *Poultry Science* 95, 1680–1692.
- Shahir, M.H., Afsarian, O., Ghasemi, S., Tellez, G., 2014. Effects of dietary inclusion of probiotic or prebiotic on growth performance, organ weight, blood parameters and antibody titers against influenza and newcastle in broiler chickens. *International Journal of Poultry Science* 13, 70–75.
- Shokaiyan, M., Ashayerizadeh, O., Shams Shargh, M., Behrouz, D., 2019. The effect of fucoidan, probiotic and antibiotic on growth indices, gut microbiota and blood parameters in broiler chickens. *Research on Animal Production* 10, 10–17.
- Sieuwers, S., De Bok, F.A.M., Mols, E., De Vos, W.M., Van Hylckama Vlieg, J.E.T., 2008. A simple and fast method for determining colony forming units. *Letters in Applied Microbiology* 47, 275–278.
- Sohail, M.U., Hume, M.E., Byrd, J.A., Nisbet, D.J., Ijaz, A., Sohail, A., Shabbir, M.Z., Rehman, H., 2012. Effect of supplementation of prebiotic mannan-oligosaccharides and probiotic mixture on growth performance of broilers subjected to chronic heat stress. *Poultry Science* 91, 2235–2240.
- Sugiharto, S., Isroli, I., Yudiarti, T., Widiastuti, E., 2018. The effect of supplementation of multistrain probiotic preparation in combination with vitamins and minerals to the basal diet on the growth performance, carcass traits, and physiological response of broilers. *Veterinary World* 11, 240–247.
- Tsirtsikos, P., Fegeros, K., Balaskas, C., Kominakis, A., Mountzouris, K.C., 2012. Dietary probiotic inclusion level modulates intestinal mucin composition and mucosal morphology in broilers. *Poultry Science* 91, 1860–1868.
- Wang, X., Zhang, P., Zhang, X., 2021. Probiotics Regulate Gut Microbiota: An Effective Method to Improve Immunity 26, 6076.
- Yang, Y.J., Sheu, B.S., 2012. Probiotics-containing yogurts suppress helicobacter pylori load and modify immune response and intestinal microbiota in the helicobacter pylori-infected children. *Helicobacter* 17, 297–304.