

Adenocarcinoma of Nictitans Gland in a Cow- A Case Report

Suresh Kumar R.V.¹, Veena P.¹, Sankar P.*¹, Dhanalakshmi N.¹, Kokila S.¹, Ch.Srilatha²

¹Department of Veterinary Surgery and Radiology, College of Veterinary Science, Sri Venkateswara Veterinary University, Tirupati-517 502 (AP), India.

²Department of Pathology, College of Veterinary Science, Sri Venkateswara Veterinary University, Tirupati-517 502 (AP), India.

(Received 1 May 2011/ Accepted 7 May 2011)

Abstract

A 7 year old cow was presented to the College of Veterinary Science clinic (Sri Venkateswara Veterinary University, Tirupati, India), with the history of growth appeared on the third eyelid of the left eye. The mass was surgically excised, and subjected to histopathological examination. Histopathological examination revealed lobules of irregular size and shape with proliferated cells, which were arranged as small tubules with or without necrotic centers. Cells were anaplastic, large and irregular with hyperchromatic nuclei. Acini showed many layers of cells with papillary projections. Mitotic figures were also present.

Keywords: Adenocarcinoma; Cow; Nictitans gland

Introduction

The membrane nictitans of buffaloes is better developed than other domestic ruminants. The rigidity to the third eyelid is provided by T shaped hyaline cartilage. The primary function of the third eyelid is to remove foreign bodies and to disperse the tear film over the eyeball. The membrane is passively swept over the globe when retractor bulbi muscle pulls it caudally. Painful intraocular diseases cause protrusion of the membrane nictitans (Tyagi and Jit Singh, 1995). The carcinoma of the gland of the third eyelid (nictitans) is a rare, sporadically occurring, invasive, solid neoplasm presenting as a mass lesion at the base of the nictitans and the ventro median conjunctiva (Meuten, 2002).

Case History

A 7 year old cow was presented to the College of Veterinary Science clinic (Sri Venkateswara Veterinary University, Tirupati, India), with the history of growth (5.0 cm in diameter) appeared on the third eyelid of the left eye. There was a gradual in-

crease in size, the growth was irregular and hard (Fig.1). Hematological and biochemical parameters were within the normal physiological limits (data not shown). It was diagnosed as a case of tumor involving the left third eyelid and the mass was surgically excised.

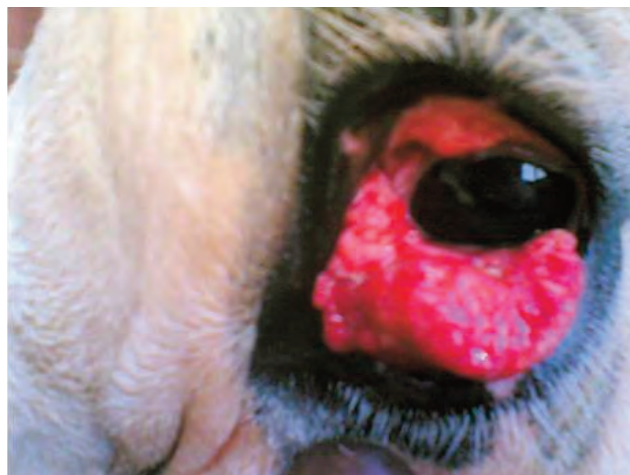

Fig.1. Nictitans gland tumor in the third eyelid.

Treatment and Results

The animal was sedated with xylazine hydrochloride at 0.01mg/kg body weight intramuscularly. The animal was restrained on lateral recumbency, lignocaine hydrochloride 2% was infiltrated at the base of the tumor mass and was surgically excised. The mass was subjected for histopathological examination. Section showed lobules of irregular size

*Corresponding author: Sankar P.

Address: Department of Veterinary Surgery and Radiology, College of Veterinary Science, Sri Venkateswara Veterinary University, Tirupati-517 502 (AP)

E-mail address: sansurvet@gmail.com

and shape (Fig. 2), with proliferated cells, which were arranged as small tubules with or without necrotic centers. Cells were anaphylactic, large and irregular with hyperchromatic nuclei. Acini showed many layers of cells with papillary projections. Mitotic figures were also present.

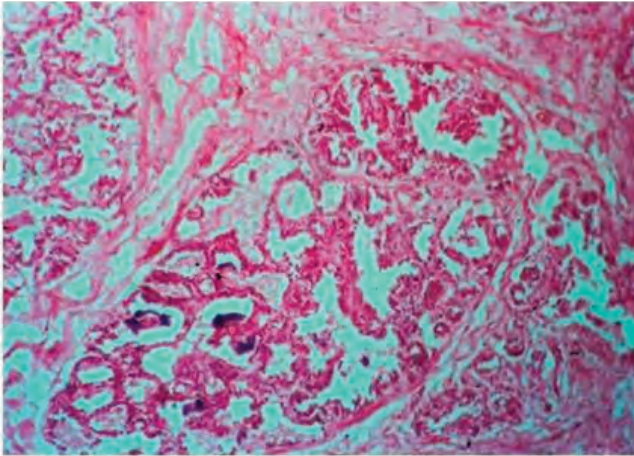


Fig. 2. Photomicrograph showing lobules of irregular size and shape, with proliferated cells, which were arranged as small tubules with or without necrotic centers (H&E $\times 70$).

The present case reported adenocarcinoma of nictitans gland in a cow and its surgical management. Animal made an uneventful recovery.

References

- Meuten, D.J., 2002. Tumors in domestic animals. 4th edition, Blackwell publishers, Iowa, pp. 60-61.
- Tyagi, R.P.S., Jit Singh, 1995. Ruminant Surgery. CBS Publishers and Distributors, Delhi, pp. 400-401.