

Effect of Four Irrigation Solutions on the Intraocular Pressure and Total Bacterial Count of the Normal Eye in Dogs

Mohammed A.H. Abdelhakiem^{1*}, Abdelbaset E. Abdelbaset²,
Mohamed R.F. Farghali³

¹Department of Animal Surgery, Faculty of Veterinary Medicine, Assiut University, Assiut 71526, Egypt.

²Department of Animal Medicine, Clinical Laboratory Diagnosis Division, Faculty of Veterinary Medicine, Assiut University, Assiut 71526, Egypt.

³Department of Animal Hygiene, Faculty of Veterinary Medicine, Assiut University, Assiut 71526, Egypt.

ARTICLE INFO

Original Research

Received:

27 September 2017

Accepted:

23 October 2017

Keywords:

Bacterial count, Dogs,
Eye, Irrigation solution,
Intraocular pressure (IOP)

ABSTRACT

There are numerous agents that have been used for irrigation of the ocular tissue from attached foreign bodies, inflammatory exudate and microorganisms. For evaluation of four agents of these irrigation solutions, sixteen clinically healthy dogs of both sexes were used in this study. The dogs were allocated into four equal groups. The right eye of dogs for each group was irrigated 3 times daily for three successive days. The groups were irrigated as following: The first group: ringer's lactate, the second group: normal saline 0.9%, the third group: boric acid 2% and sodium bicarbonate 1% was used for the fourth group. The left eye was considered control one. The results revealed that the four solutions did not cause any obvious alteration of the eyes and change the intraocular pressure (IOP). According to their effects on the total bacterial count, the four irrigation solutions had not any significant effect. It could be concluded that all of these agents may be used for irrigation of the intact eye and removal of the attached exudate and foreign bodies.

J. Adv. Vet. Res. (2017), 7 (4), 120-124

Introduction

Although the globe is impervious to events that occur in other body tissues, it is highly sensitive to any lesion occurs elsewhere in the eye itself. In fact, the intraocular environment has not resident defenses and self-cleansing mechanism like peristalsis or coughing. The inflammation can occur either in the intraocular or periocular tissues. The injury or inflammation of the eye resulted from a wide variety of factors, such as trauma, infectious agents, irradiation, chemicals, nutritional deficiencies or excesses, immune mediated, neoplasia, genetic and toxicities. The affections of the eye in the pet animals are numerous (Wilcock, 2008). The exudate is considered one of the byproducts of the inflammatory process, which may cause several problems such as blepharitis, periocular dermatitis and sticky eye (Maggs, 2008). The cleansing agents or irrigation solutions could be used for preparation of the eye immediately before surgery in a process called chemical preparation

of the eye as was exhibited by Isenberg *et al.* (1983). The importance of the irrigation solutions could be summarized in 3 benefits, according to Isenberg *et al.* (1983). First, to clean up debris, mucus, or other unnecessary substances that might be adhered to the conjunctiva or cornea. Second, to remove the iatrogenic placed substances which are thought that may have antibacterial effects. Third, to provide a condition of aseptis to eye by washing the microorganisms. There are many of isotonic solutions that are used as a cleansing agent for removal of the purulent exudate, foreign bodies and irritants (Crispin, 2005; Maggs, 2008). The physiological saline, ringer's lactate, sodium bicarbonate, boric acid solution, tap water, normal saline adjusted to pH 7.4 with sodium bicarbonate (NS + Bicarb), sodium ascorbate, sodium citrate and other agents are examples of the solutions that are safe for irrigation and washing of the eye (Apt and Isenberg, 1982; Isenberg *et al.*, 1983; Herr *et al.*, 1991; Pfister *et al.*, 1991; Ishii *et al.* 1993; Joussem *et al.*, 2000; Ikeda *et al.*, 2006). In the literature, there is little information about the different cleansing agents of the eye in small animals. The available literature lacks any significant information about the effect of ringer's lactate, normal saline, boric acid 2% and Na bicarbonate on the total bacteria of the normal or diseased eyes in animals. The aim of this study was

*Corresponding author: Mohammed A. H. Abdelhakiem
E-mail address: hamdsurgery@yahoo.com

to compare the effect of four different solutions on the ocular structures, and the intraocular pressure (IOP). As well as, the antibacterial effect of these agents was investigated.

Materials and methods

Animals

The study protocol was approved by the institutional ethics committee of the faculty of veterinary medicine, Assiut University, Egypt. The study was carried out on 16 apparently healthy mongrel dogs. The age of the animals ranged from 1-4 years (mean= 2 years), and they weighted from 8-15.5 kg (mean=12.25) and the gender of these dogs were 12 intact females and 4 intact males. All animals were subjected to the clinical examination. They had received an ophthalmic examination, including the naked eye examination using focal light source in a semi-darkened room. The dogs were healthy and devoid of any signs of the ocular lesions. The animals were divided into 4 groups; each had 4 dogs.

Chemicals and Equipments

Normal saline (0.9% NaCl, Egypt Otsuka pharmaceutical Co. S.A.E. 10th of Ramadan City, Cairo, Egypt). Ringer's lactate (Egypt Otsuka pharmaceutical Co. S.A.E. 10th of Ramadan City, Cairo, Egypt). Boric acid 4% (Alaazapy Pharmacy, Assiut, Egypt) was diluted with an equal volume of distilled water. Sodium Bicarbonate 1gram capsules (Alaazapy Pharmacy, Assiut, Egypt), was prepared into 1% solution using distilled water. Xylazine Hcl (Xyla-ject 2%; 1mL=20 mg, Adwia Co. S.A.E. 10th of Ramadan City, A.R.E). Lidocaine HCl (Debocaine 2%; Sigma-Tec pharmaceutical Indust. Co. Packed by: AL-Debeiky Pharmaceutical Industries Co., for: AL-Debeiky Pharma – Egypt). Schiotz tonometer (Sklar, New York, NY).

Study design

Four different cleansing agents were used. The right eye was irrigated 3 times daily for 3 consecutive days. The left eye was not irrigated and was considered as a control one.

All the animals were tranquilized using 1 mg /kg of xylazine Hcl. Five drops of lignocaine Hcl were applied on the corneal surface before using the Schiotz indentation tonometer (5.5 gram weight). Three readings by tonometer were obtained for each eye when the head of the animal was directed vertically (the nose was upward). The mean value of the three obtained values of IOP using Schiotz tonometer for each eye was converted into mmHg by Canine calibration table. Fluorescein staining of the right and left eyes were done for detection of any corneal lesion before application of the cleansing agents.

Before the irrigation process, a swab was taken from each of the right and left eyes for bacteriological examination. The swab included the conjunctival sacs, the corneal surface and the palpebral and bulbar surfaces of the nictitating membrane. The collected swabs were kept in sterilized tubes containing sterilized broth. They were sent to the bacteriological laboratory of Animal Hygiene Department, Faculty of Veterinary Medicine, Assiut University, Egypt in an ice box (4°C) within 2 hours from sample collection.

The dogs of group (1), group (2), group (3) and group (4) were treated using Ringer's lactate, normal saline 0.9, boric acid 2% and Na bicarbonate 1% respectively. The right eye was irrigated three times daily with 1 mL of the solution for three successive days.

After the 3-day's irrigation, the second swab was obtained from each of the treated and control eyes in the same way as

pre-irrigation swabs. The intraocular pressure of both eyes was measured and recorded. The fluorescein staining of the dog's eyes was carried out to determine any corneal lesion.

The treated eyes were inspected after their irrigation. The ocular discharge, the conjunctival hyperemia, the pupil size, the periorbital swellings and the reaction of the animal to cleansing agents were taken in consideration and the treated right eye was compared with the left (control) eye.

The obtained data of the intraocular pressure and bacteriological examinations of both eyes before and after their wash were recorded on an Excel spreadsheet for the statistical analysis. The examinations, tonometry and swabbing were performed by the same examiner.

Enumeration of total viable bacteria

The laboratory examination was performed using the pour plate method for counting of colony-forming units (CFU/mL) on standard Plate Count Agar (LAB M, Lab149, United Kingdom), according to APHA (2005). The swab samples in the sterile saline were thoroughly mixed, then one millilitre of the sample was aseptically transferred to a sterilized petridishes in duplicates. Ten millilitre of the sterile dissolved plate count agar media were cooled in a water bath to a temperature of 44°C and poured aseptically to each plate, each dish was moved in a circular motion several times to thoroughly mix of the sample with the medium. The plates were left until the hardening of the medium, then they were incubated upside down in the incubator at a temperature of 37°C for 24 hrs. After incubation, the total number of each replicates of the sample was counted; the mean number of CFU was extracted and multiplied by the inverse of dilution. The resulting colonies were expressed as CFU/mL (APHA, 2005).

Statistical analysis

Data were analyzed using a commercially available software package (GraphPad Prism Version 5.0, GraphPad Software). The statistical analysis was performed to determine the changes in the IOP and total bacterial counts before and after irrigation in the different groups, using one-way ANOVA and T test. Values of $P < 0.05$ were considered significant. As well as, the difference of the overall means of the bacterial count between the right and left eyes before and after irrigation were analyzed using T test. The correlation between the age, weight and sex relative to the IOP was determined.

Results

The daily clinical examination of the eyes showed that the four used cleansing agents had not any harmful effect on the ocular structures. Discharges, periorbital swelling, engorgement of conjunctival blood vessels, protrusion of the nictitans membrane, and change of the pupil size were not noticed in the treated eyes.

The results of the fluorescent staining were negative, and none of the irrigation solution left any fluorescent stained lesion (ulcer) on the cornea.

There were no significant changes in the IOP in the treated eye after irrigation for 3 successive days in the 4 groups. The P value and r^2 were (0.9617 and 0.02305; 0.9983 and 0.002737; 0.3997 and 0.2105 and 0.1860 and 0.3202) for groups 1, 2, 3 and 4 respectively.

The values of the IOP (mean \pm SD and range) in the treated and control eyes before and after irrigation of the four groups are summarized in Table 1. The correlation between the age of animals and IOP was detected only in the left eye before irrigation ($r = -0.6795$ and $P = 0.0038$), however the correlation

between the weight of dogs and IOP was detected in the right eye after irrigation ($r= 0.5234$, $P= 0.0375$). There was no correlation between the sex and the IOP in dogs ($P= 0.356$).

Table 1. The values of IOP before and after application of the irrigation solutions of the treated and unirrigated (control) eyes.

Group		Mean± SD (mmHg)	Range (mmHg)
Ringer's lactate			
Right	Before	27.38±6.5	18.6-33.9
	After	25.75±5.52	18.6-30.1
Left	Before	25.75±5.52	18.6-30.1
	After	27.23±5.75	18.6-30.1
Normal saline 0.9%			
Right	Before	30.25±2.86	26.9- 33.9
	After	30.1	30.1
Left	Before	30.1	30.1
	After	30.1	30.1
Boric acid 2%			
Right	Before	27.6± 5.0	20.1-30.1
	After	31.05±1.9	30.1-33.9
Left	Before	26.05± 7.04	20.1-33.9
	After	31.35±4.87	26.9-38.3
Na bicarbonate 1%			
Right	Before	31.05±1.9	30.1-33.9
	After	24.35±6.64	18.6-30.1
Left	Before	30.25±2.86	26.9-33.9
	After	26.43±5.43	18.6-30.1

Although the statistical analysis using ANOVA showed the significant difference in the total bacterial count in the first and second groups (RL and NS) ($P= 0.0155$ and 0.0173 respectively), there is no obvious difference in the total bacterial count in the treated eye of both groups before and after irrigation using T test ($P= 0.1486$ and 0.3278 respectively) (Fig. 1 A and B).

Regarding to the boric acid group, there was a significant increase in the total bacterial count of control eye ($P= 0.0197$) before and after irrigation. However, the treated eye did not show any significant difference ($P= 0.3844$) (Fig. 1C).

The results of the fourth group (Na bicarbonate 1%) were not significant according to the effect of the solution on the number of bacteria in the treated eye ($P= 0.1765$) (Fig. 1D).

There was no significant difference between the total bacterial count in the left and right eyes of the 16 dogs before irrigation ($P= 0.428$). However, the P value was 0.0105 (significant) for the difference between the bacterial count in the left and right eyes of 16 dogs after irrigation.

There was a significant difference of the total bacterial count in the left eyes of 16 dogs before and after irrigation ($P= 0.0016$), while the P value (0.8792) was considered non-significant for the right eyes of all dogs before and after irrigation.

Discussion

The use of different irrigation solutions of the eye is so crucial for the provision of the ocular tissue with agents that may reduce or counteract the effect of the noxious stimuli causing ocular injury, inflammation or damage and may threaten the visual function.

In this study four cleansing agents were used and their ef-

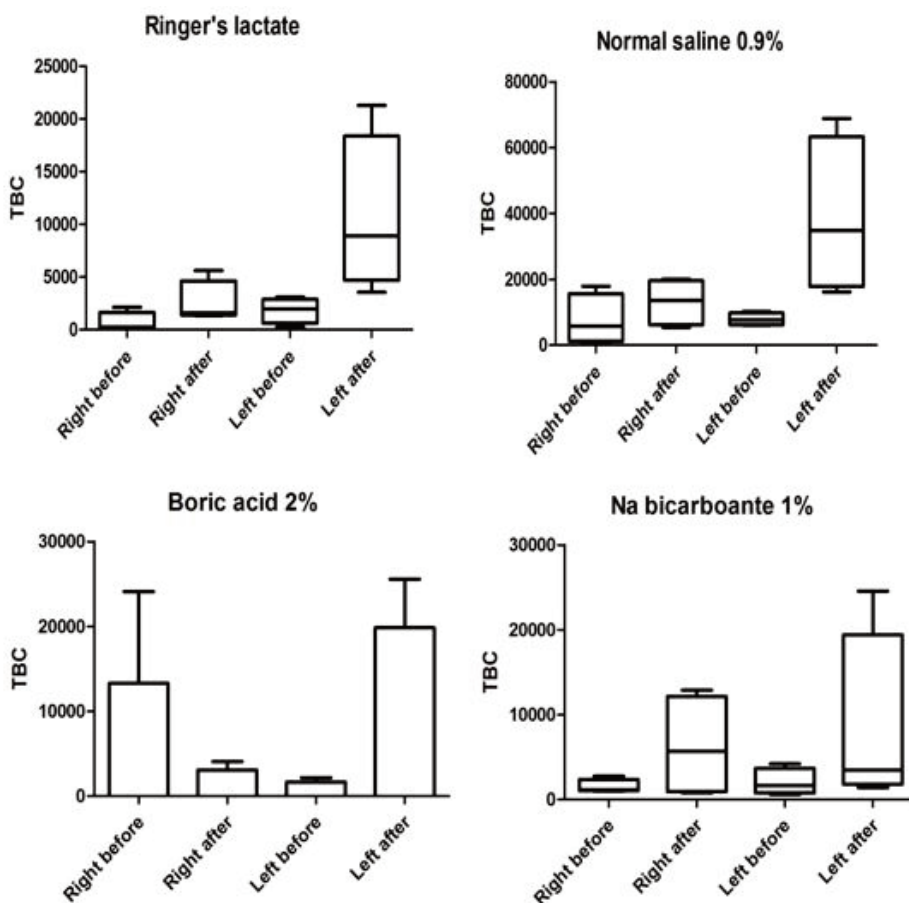


Fig. 1. The total bacterial count of the treated and control eyes before and after irrigation, and effect of irrigation solutions on TBC in the treated eye.

fects were compared to determine which one will be appropriate for use.

The results of this study revealed that the use of any of the four irrigation solutions (ringer's lactate, normal saline 0.9%, boric acid 2% and sodium bicarbonate 1%) did not leave any obvious detrimental effect when the clinical examination of the eye was done daily. These results were consistent with the results of other studies (Apt and Isenberg, 1982; Isenberg *et al.*, 1983, Herr *et al.*, 1991; Pfister *et al.*, 1991; Ishii *et al.*, 1993; Jousen *et al.*, 2000; Saidinejad and Burns, 2005; Ikeda *et al.*, 2006). The safety of these solutions on the ocular tissue may be attributed to the isotonicity of the used agents which did not absorb or add fluids from or into the ocular tissue, as was explained by Mathews (2006) and DiBarrola and Bateman (2006). However, Mikuni (1976) reported in his study the opposite effect of the prolonged intra-operative use of ringer's lactate which may damage the ocular tissue.

The studies which were carried out by Gelatt and MacKay (1998) in dogs and Mori *et al.* (2000) in human, reported the negative correlation between the age and the intraocular pressure. However, Heywood (1971) recorded the opposite results in Beagle dogs. In this study, there was no correlation between the age of dogs and the measured intraocular pressure except between the age of dogs and the intraocular pressure of the control eye before the beginning of the irrigation ($r = -0.6795$). The lack of association between age of dogs and IOP in this study was consistent with the results of a previous study, which was conducted by Pauli *et al.* (2006). This variation of results may be attributed to first, the tool used for measurement of IOP in each study. In the present work, Schiottz indentation tonometry was used, while in the previous study was performed by Gelatt and MacKay (1998), four applanation tonometers were used. Second factor which may result in different results of the present work relative to the study of Gelatt and MacKay (1998), is the range of dogs' age. The range of dogs in the present study was 1-6 years.

The results of this study revealed the lack of correlation between the weight of dogs and the IOP except in the treated eye after irrigation ($r = 0.5234$, $P = 0.0375$). These results were inconsistent with the results of the previous study, which was performed by Mori *et al.* (2000). That study revealed the correlation between the body mass index and the IOP in Japanese provided controlling of age, gender and blood pressure.

The results of the present work showed the lack of association between the sex of the animals and IOP. These results differs than the results of Mori *et al.* (2000), who reported the increase of IOP in male than females.

All values of the IOP of both treated and control eyes of all dogs ranged from (18.6- 33.9 mmHg) using the canine calibration table. All of the obtained data were considered normal according to the results of other studies (Magrane 1951; Gelatt and MacKay, 1998). In the study, which was carried out by Miller and Pickett (1992), the obtained values of IOP using Schiottz tonometer and canine calibration table were much higher than what were obtained using either applanation tonometer or Schiottz tonometer using human calibration table.

The results of this study proved that the lack of effect of ringer's lactate, normal saline 0.9%, boric acid 2% and Na bicarbonate 1% on the total bacterial count in the eye. Actually, to our knowledge, there were no studies in the literature evaluating the effect of these aforementioned agents on the TBC in the eye either the normal or diseased one. But, the effect of these agents on other tissue, other than the eye was displayed in other studies. Houtsma (1996) stated the antibacterial effect of the sodium lactate, which is considered one of the four components of ringer's lactate. Fernandez *et al.* (2004) and Griffiths *et al.* (2001), reported the lack of effectiveness of

normal saline on the infection rate of the cleansed wounds. Corral *et al.* (1988) reported the antimicrobial effect of sodium bicarbonate in vitro. Drake (1997) recorded the antibacterial effect of sodium bicarbonate (baking soda) against *Streptococcus mutans* causing oral lesions. Richards and McBride (1971) used the sodium bicarbonate as a preservative of eye lotion against the contamination with *Pseudomonas aeruginosa*. Letscher-Bru *et al.* (2013), documented the effect of sodium bicarbonate against the most common strains of fungi affecting the skin and nails in human. There were several studies that reported the germicidal or the antimicrobial effect of boric acid in different tissue other than the eye. Maggs (2008), reported that the boric acid has a weak germicidal effect. Abercrombie (2010); lavazzo (2011) and NCI (2017) recorded the antiseptic effect of boric acid to be used for minor burns or cuts and sometimes as a component of dressings or salves. Moreover, it can be used as a vaginal douche to treat bacterial vaginosis due to excessive alkalinity, vaginal candidiasis, acne treatment, prevention of athlete's foot, treat some kinds of otitis externa (ear infection) in both humans and animals. So, according to the above mentioned previous studies, no study discussed the direct effect of ringer's lactate, normal saline, boric acid 2% and sodium bicarbonate on the normal or diseased ocular tissue.

The results of the statistical analysis of the overall mean of the total bacterial count of all dogs in the right and left eyes revealed the lack of significant difference ($P = 0.4284$) between the right and left eyes before irrigation. However, there was a substantial change in the bacterial count between the right and left eyes after irrigation ($P = 0.0105$). This means the irrigation solutions had an antibacterial effect even if this effect was not appeared clearly in groups of ringer's lactate, normal saline and Na bicarbonate 1%. This result was approved through the other results of statistical analysis which showed the significant increase of the bacterial count in the left (control) eyes before and after irrigation ($P = 0.0016$). However, the treated eye did not show any significant change in the bacterial count before and after irrigation ($P = 0.8792$). The left and right eyes of each animal were subjected to the same environment. The lack of variance of the bacterial count between the right and left eyes of all dogs before irrigation, the significant increase of bacterial count of the left eyes after 3 days, the steady number or nonsignificant decrease of the bacterial count of the right eyes after 3 days of irrigation proved the valuable effect of the used irrigation solutions for control of infections in dog's eye.

The limitations of this study, The obtained swabs from each eye, even by the same examiner may not result in accurate counting of the bacteria. Moreover, the effect of cleansing agents in this study on the pathogenic microorganisms was not determined. So the authors recommended a further study to determine the effect of these cleansing agents on the ocular lesions especially the corneal ulcers.

Conclusion

From the results of this study, it could be concluded that the safe use of ringer's lactate, normal saline 0.9%, boric acid 2% and Na bicarbonate 1% for irrigation of the intact eye and removal of the attached exudate and foreign bodies.

Acknowledgement

The authors have thanked the staff members of Animal Surgery Department for provision of materials of this work, reviewing and revision of the manuscript before publishing.

References

- Abercrombie, P., 2010. Vaginitis. In: Maizes, V., Low Dog, T. Integrative Women's Health. New York, NY. Oxford University Press. p. 192. ISBN 978-0-19-537881-8.
- APHA (American Public Health Association), 2005. Standard methods for the examination of water and wastewater. 21 Ed., APHA, Inc. Washington D.C.
- Apt. L., Isenberg, S., 1982. Chemical preparation of skin and eye in ophthalmic surgery. An international survey. *Ophthalmic Surg.* 13, 1026-1029.
- Corral, L.G., Post, L.S., Montville, T.J. 1988. Antimicrobial activity of sodium bicarbonate. A research note. *J. Food Sci.* 53, 981-982.
- Crispin, S., 2005. Notes on Veterinary Ophthalmology. 1st edition. Blackwell Science.
- DiBarrola, S.P., Bateman, S., 2006. Introduction to fluid therapy. In: Fluids, electrolytes and acid base disorders in small animal practice. 3rd ed. Elsevier. USA. pp. 325-344.
- Drake, D., 1997. Antibacterial activity of baking soda. *Compend Contin. Educ. Dent. Suppl.* 18(21), 17-21.
- Fernandez, R., Griffiths, R., Ussia, C., 2004. Effectiveness of solutions, techniques and pressure in wound cleansing. *JBIR REPORTS* 2, 231-270.
- Gelatt, K.N., MacKay, E.O. 1998. Distribution of intraocular pressure in dogs. *Vet. Ophthalmol.* 1, 109-114.
- Griffiths, R., Fernandez, R., Ussia, C. 2001. Is tap water a safe alternative to normal saline for wound irrigation in the community setting?. *Journal of Wound Care* 10 (10), 407-411.
- Herr, R., White, G., Bernhisel, K., Mamalis, N., Swanson E., 1991. Clinical comparison of ocular irrigation fluids following chemical injury. *Am. J. Emerg. Med.* 9, 228-231.
- Heywood, R. 1971. Intraocular pressures in the Beagle dog. *Journal of Small Animal Practice* 12, 119-121.
- Houtsma, P.C., 1996. Antimicrobial activity of sodium lactate. Ph.D. thesis, Agricultural University Wageningen, Netherlands.
- Iavazzo C., Gkegkes I.D., Zarkada I.M., Falagas M.E., 2011. Boric acid for recurrent vulvovaginal candidiasis. the clinical evidence. *J. Womens Health (Larchmt)* 20 (8), 1245-1255.
- Ikeda, N., Hayasaka, S., Hayasaka, Y., Watanabe, K., 2006. Alkali Burns of the Eye. Effect of Immediate Copious Irrigation with Tap Water on Their Severity. *Ophthalmologica* 220, 225-228.
- Isenberg, S., Apt, L., Yoshimuri, R., 1983. Chemical Preparation of the Eye in Ophthalmic Surgery. I. Effect of Conjunctival Irrigation *Arch Ophthalmol.* 101, 761-763.
- Ishii, Y., Fujizuka, N., Takahashi, T., Shimizu, K., Tuchida, A., Yano, S., Naruse, T., Chishiro, T. 1993. A fatal case of acute boric acid poisoning. *Clinical Toxicology* 31 (2), 345-352.
- Joussen, A.M., Barth, U., Cubuk, H., Kock, H., 2000. Effect of irrigating solution and irrigation temperature on the cornea and pupil during phacoemulsification. *J. Cataract Refract Surg.* 26, 392-397.
- Letscher-Bru, V., Obszynski, C. M., Samsoen, M., Sabou, M., Waller, J., Candolfi, E., 2013. Antifungal Activity of Sodium Bicarbonate Against Fungal Agents Causing Superficial Infections. *Mycopathologia* 175 (1-2), 153-158.
- Maggs, D.J., 2008. Conjunctiva. In: Slatter's fundamentals of veterinary ophthalmology (Maggs, D., Miller, P. and Ofri, R. Eds). 5th edition. Elsevier Health Sciences. pp. 140- 152.
- Magrane, W.G., 1951. Tonometry in ophthalmology. *North American Veterinarian* 32, 413- 415.
- Mathews, K.A., 2006. Monitoring of fluid therapy and complications of fluid therapy. In: Fluids, electrolytes and acid base disorders in small animal practice. 3rd ed. Elsevier. USA. pp. 377-391.
- Mikuni, M.D., 1976. Intraocular irrigating solutions and lens clarity. *American Journal of Ophthalmology* 82 (4), 594- 598.
- Miller, P.E., Pickett, J.P., 1992. Comparison of the human and canine Schiotz tonometry conversion tables in clinically normal dogs. *J. Am. Vet. Med. Assoc.* 201(7), 1021-1025.
- Mori K., Ando, F., Nomura, H., Sato, Y., Shimokata, H., 2000. Relationship between intraocular pressure and obesity in Japan. *International J. of Epidemiology* 29, 661-666.
- National cancer institute (NCI). 2017. Boric Acid (Code C47416). <https://ncit.nci.nih.gov>. Version. 17.06d.
- Pauli, A.M, Bentley, E., Diehl, K.A., Miller, P.E., 2006. Effects of the Application of Neck Pressure by a Collar or Harness on Intraocular Pressure in Dogs. *Journal of the American Animal Hospital Association* 42, 207-211.
- Pfister, R.R., Haddox, J.L., Yuille-Barr, D., 1991. The combined effect of citrate/ascorbate treatment in alkali-injured rabbit eyes. *Cornea* 10, 100-104.
- Richards, R.M.E., McBride, R.J., 1971. Preservation of sodium bicarbonate eye lotion BPC against contamination with *Pseudomonas aeruginosa*. *Brit. J. Ophthal.* 55, 734- 738.
- Saidinejad, M., Burns, M.M., 2005. Ocular Irrigant Alternatives in Pediatric Emergency Medicine *Pediatric Emergency Care* 21, 23-26.
- Wilcock, B.P., 2008. General pathology of the eye. In: Slatter's fundamentals of veterinary ophthalmology (Maggs, D., Miller, P. and Ofri, R. Eds). 5th edition. Elsevier Health Sciences. pp. 62-80.