



Gross Anatomy of the Gastrointestinal Tract of a Red Brocket Deer (*Mazama americana*): A Case Study

Kegan Romelle Jones*, Kavita Ranjeeta Lall, Gary Wayne Garcia

The Open Tropical Forage-Animal Production Laboratory [OTF-APL], Department of Food Production [DFP], Faculty of Food and Agriculture [FFA], The University of the West Indies [UWI], St Augustine, Trinidad and Tobago

ARTICLE INFO

Case Report

Received:
17 May 2018

Accepted:
29 June 2018

ABSTRACT

A fresh carcass of a male red brocket deer (*Mazama americana*) was examined and dissected to macroscopically and morphometrically examine its gastrointestinal tract. It was found to have the typical rumen forestomach, consisting of the rumen, reticulum, omasum and abomasum. The tongue of the red brocket deer is pointed with a prominent torus lingua. The small intestine (4.743 m) was almost twice the length of the colon and rectum (1.940 m) and made up 65.84% of the intestinal tract, while the large intestine accounted for 35.16%. The hard palate had transverse folds which ran to the level of the premolars, leading feed into the oesophagus. These preliminary findings classified the red brocket deer as a concentrate selector ruminant. This was the first known anatomical description of the gastrointestinal tract of the red brocket deer (*Mazama americana*) documented.

Keywords:

Red brocket deer,
Anatomy, Digestive tract,
Measurements,
Forestomach, Intestine

J. Adv. Vet. Res. (2018), 8 (3), 26-31

Introduction

Ruminant animals are those with a four-compartment stomach; rumen, reticulum, omasum and abomasum. These animals include cattle, sheep, goat and deer. The true stomach or the acid pepsin stomach is the abomasum; the reticulum is so named because of the honeycomb appearance of the mucosal surface; the omasum is spherical in shape bearing leaf like folds; and the rumen is divided by pillars and bar many papillae used to increase surface area (Church, 1976, 1977). Ruminants have dental pads in the area generally occupied by upper incisors (Dyce *et al.*, 1987).

Red brocket deer (*M. americana*) are known to inhabit areas with dense vegetation and moist areas, such as swamps and marshes, although they could be found in dry forests and terra firme areas (Bodmer, 1991a; Hurtado-Gonzales and Bodmer, 2004; Tobler *et al.*, 2009; de Lázari *et al.*, 2013; Ultimate ungulate, 2017; Animalia, 2017).

They are classified as frugivorous ruminants that consume fruits, seeds, flowers, grasses and green shoots (Alkins, 1979;

Bodmer, 1989; Emmons and Freer, 1990; Bodmer, 1991b; Eisenberg and Redford, 1999). Eisenberg and Redford (1999) also described them as being browsers, while Emmons and Feer (1990) stated that they browsed mainly when fruits were scarce.

Hofmann (1989) classified ruminants into three (3) types; concentrate selectors, grass and roughage eaters and intermediate (opportunistic) feeders. Concentrate selectors are adapted to digesting plant cell contents (soluble) and high quality diets. The grass and roughage eaters forage on plants rich in cell wall. Domestic ruminants such buffaloes, cattle and sheep fall in the grass and roughage eating group. The intermediate group fall in between the groups mentioned above, their diet consists of a mixed diet but avoid fibre as much as possible. Domesticated goats fall in the category of intermediate feeder (Van Soest, 1994). Ruminants have also been classed into two groups; grazers and browsers. Grazers have a smaller true abomasum, caecum and intestines as compared to browsers. Browsers have larger foreguts as compared to the grazers. These anatomical differences ensure that browsers can digest fibrous parts of the plant and allow grazers to digest high quality forage (Shiple, 1999). Hofmann (1988) stated that the term browsers was too narrow and the term concentrate selectors, grass or roughage eaters and interme-

*Corresponding author: Kegan Romelle Jones
E-mail address: keganjones11@gmail.com

diate eater should be used.

Deer, including the red brocket deer, are ruminants, meaning that they have a four-chambered stomach. There were early publications of the gross anatomy of the digestive tract of the agouti (*Dasyprocta leporina*) (Garcia et al., 2000) and the gross anatomy of the male and female reproductive tract of the agouti (Mollineau et al., 2006; Singh et al., 2014) from Trinidad. No reference publications have been observed on the gross anatomy of the red brocket deer's gastrointestinal tract, hence the opportunity was taken to investigate this when it presented itself. The purpose of this study, therefore, was to attain the basic measurements and description of the gross appearance of the gastrointestinal tract of a mature male red brocket deer.

Materials and methods

The specimen used in this study was a four (4) year old male red brocket deer, with an estimated weight of 30 kg. It was a captive bred deer that lived in the backyard of a wildlife farmer in Diego Martin, Trinidad (Republic of Trinidad and Tobago, West Indies). On the morning (6 a.m.) of Wednesday 18th October, 2017 it was discovered under the capuchin's cage, dead, with a small pool of blood around the head (the left eyeball was punctured). A post mortem examination was conducted on the animal using standard Veterinary protocol. Trauma was indicated as the cause of death, as this deer was not observed to have been clinically ill. Dissection of the digestive tract took place five (5) hours later on the same day.

Measurements were taken externally of the deer before it was dissected via a ventral, midline incision, using scalpel blades and scissors to enter the abdominal and thoracic cavities in order to remove the entire gastrointestinal tract. The intestinal tract was tied off as close to the end of the rectum as possible, before it was cut free from connective tissue, uncoiled (intestines), washed and laid out on old feed bags in order to identify and measure (with a soft measuring tape) the different segments (tongue, oesophagus, rumen, reticulum, omasum, abomasum, small intestine, large intestine and caecum). Photographs were taken of the deer before and after dissection, with the intestinal tract and abdominal organs within the abdominal cavity, as well as after when it was placed on the old feed bags.

Results

The mouth

The hard palate was pink with prominent transverse folds (*Ruguae palatinae*), which had serrated edges and a prominent cream coloured incisive papilla. The transverse folds in the hard palate of *M. americana* ran throughout the hard palate. The transverse folds were directed caudally to allow feed to move from the mouth to the oesophagus. The transverse folds on the hard palate got smoother caudally and ended at the level of the premolar teeth. The entire mucosal cheek surface had pink, elongated, caudally pointed (mucosal) papilla. The dental formula was I 0/3, C 0/1, P 3/3 and M 3/3 = 32, with a diastema between the lower canines and premolars (Figs. 1 and 2). It had a pink, pointed, spatula-shaped tongue (0.140 m in length) with a raised area (torus lingua), which had prominent papilla, running from the centre to the caudal area of the tongue (Fig. 3).

The oesophagus

The oesophagus was a pink, cylindrical tube measuring 0.500 m in length, running ventrally to the trachea and enter-

ing the rumen (Figs. 4 and 5).

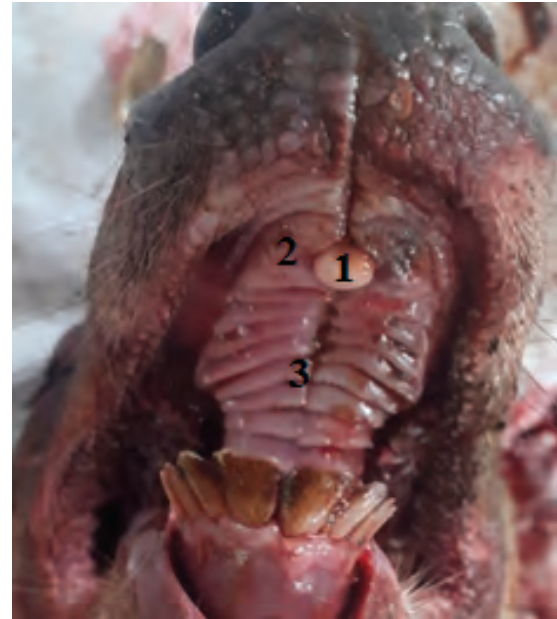

Fig. 1. Open mouth photograph of the inside of the Mouth. 1) incisive papilla; 2) hard palate and 3) Transverse folds (*Ruguae palatinae*).

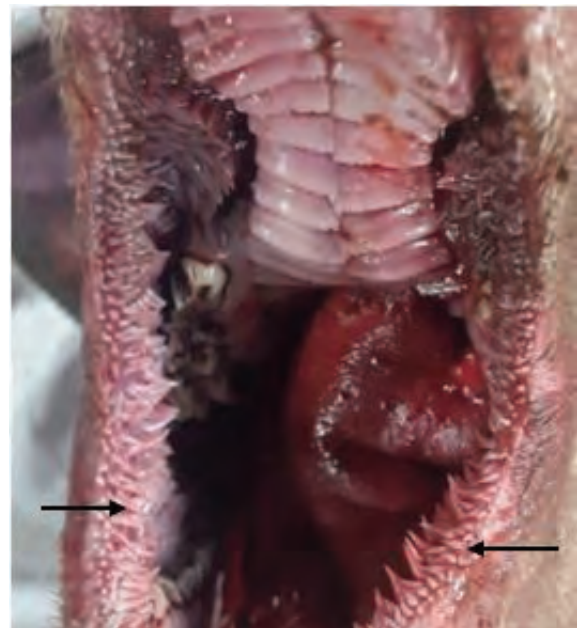

Fig. 2. Photograph showing the mucosal papillae on the mucosal surface of the cheek (denoted by arrows).

Table 1. The external measurements of the red brocket deer specimen

Feature	Measurement (metre)
Nose to rump	1.000
Girth	0.711
Height (withers to hoof) /point of shoulder	0.602

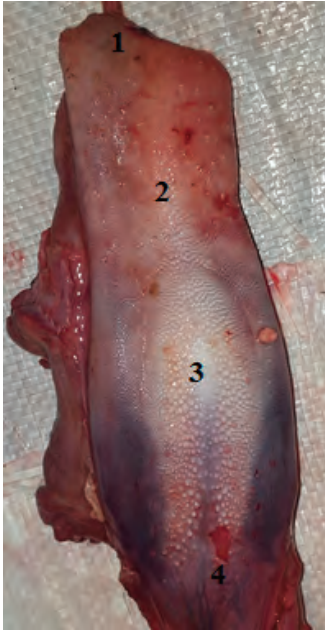

Fig. 3. Photograph of the dorsal surface of the tongue. 1) apex; 2) body; 3) torus lingua and 4) radix lingua.

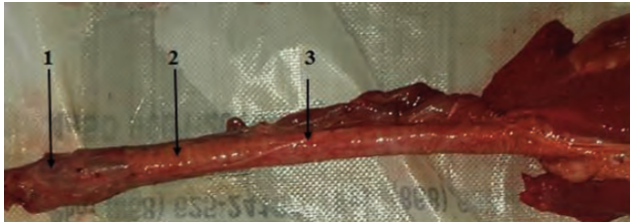

Fig. 4. Photograph showing the oesophagus running ventrally to the trachea. 1) larynx; 2) trachea and 3) oesophagus.

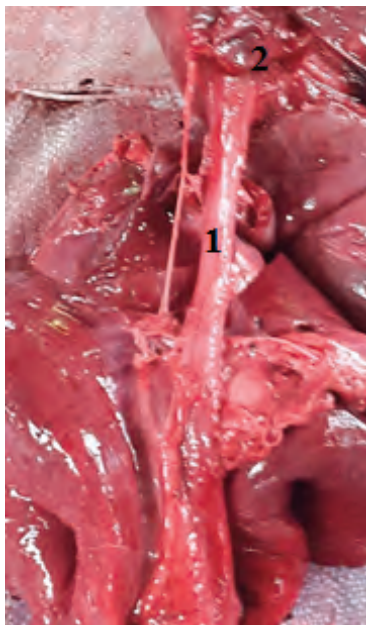


Fig. 5. Photograph of the oesophagus entering the rumen. 1) oesophagus and 2) rumen.

The forestomach and abomasum

The red brocket deer showed the classical four-chambered stomach of ruminants (Figs. 6-10). The rumen was light grey and light pink in colour with evenly distributed papillae over the entire mucosal surface. The lengths of the dorsal and ven-

tral sacs of the rumen were 0.311 m and 0.220 m respectively, with a ruminal height of 0.230 m. The caudo-ventral blind sac projected more caudally than the dorsal blind sac. The border of the intra-ruminal ostium was formed by the ruminal pillars. The omasum was light pink in colour and measured 0.060 m (long axis) and 0.051 m (short axis) in length, with multiple inner longitudinal folds, covered by papillae. It was situated cranio-dorsally to the rumen. The reticulum was light pink in colour and the mucosal surface had a honey-combed appearance. It was situated cranio-ventrally to the rumen and measured 0.090 m in length and 0.050 m in height. The abomasum was situated medially to the rumen and was light pink in colour. It measured 0.272 m (greater curvature) and 0.156 m (lesser curvature) and the mucosal surface had folds (Table 2).

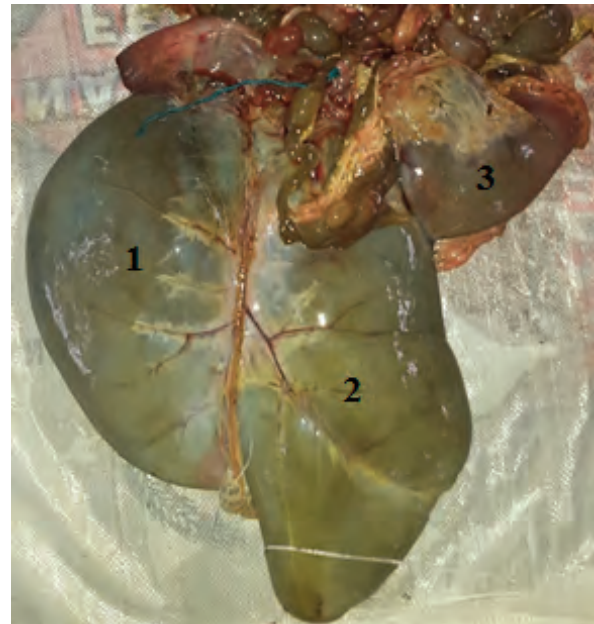


Fig. 6. Photograph showing the ventral aspect of part of the forestomach and spleen. 1) Dorsal blind sac of the rumen; 2) Caudo-ventral blind sac of the rumen. 3) Spleen.

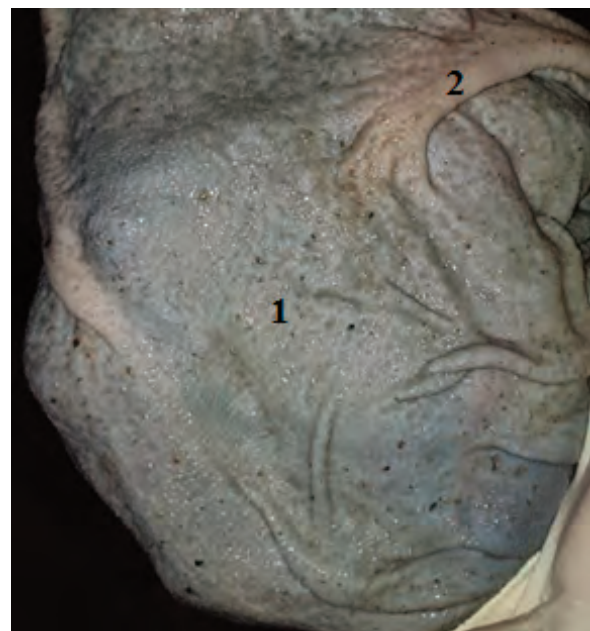


Fig. 7. Photograph showing the mucosal surface of the rumen. 1) Mucosal surface with papillae. 2) Ruminal pillar.

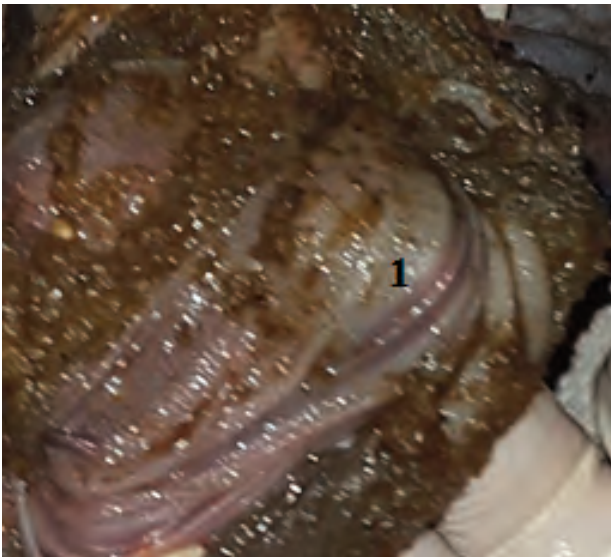


Fig. 8. Photograph of the mucosal surface of the abomasum. 1) Folds on the mucosal surface with papillae.

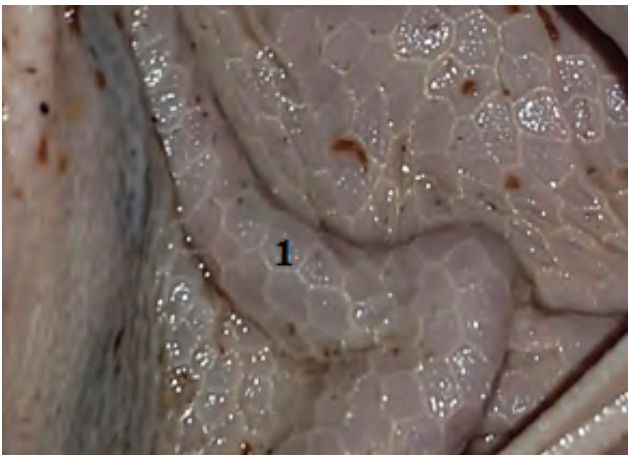


Fig. 9. Photograph of the mucosal surface of the reticulum. 1) Honey-combed appearance.

Table 2. The lengths of each region of the gastrointestinal tract

Region	Length (metre)
Tongue	0.140
Oesophagus	0.500
Reticulum	0.090 (long axis) 0.050 (height)
Rumen	0.311 (dorsal sac) 0.220 (ventral sac) 0.230 (height)
Omasum	0.060 (long axis diameter) 0.051 (short axis diameter)
Abomasum	0.272 (greater curvature) 0.156 (lesser curvature)
Small intestine	4.743
Large intestine:	2.470
Colon	1.680
Caecum	0.260 (apex-base)
Rectum	0.530
Length of digestive tract	8.446

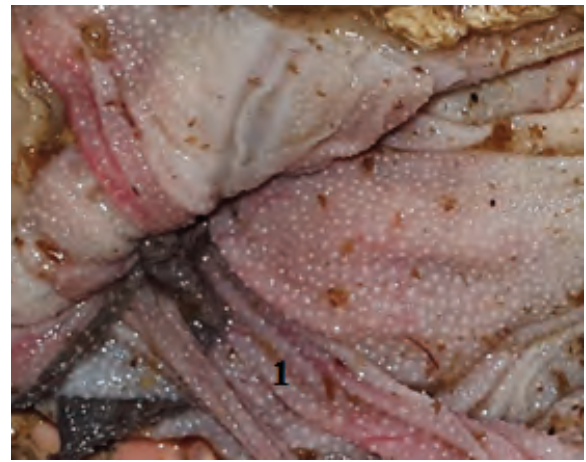

Fig. 10. Photograph of the mucosal surface of the omasum. 1) Inner mucosal folds and papillae.

The small and large intestines

The small intestine was highly coiled and measured 4.743 m in length when uncoiled. The colour varied from pink to grey and green (Fig. 11). The total length of the large intestine and caecum was 2.470 m when uncoiled. The caecum measured 0.260 m (apex-base length). Part of the colon also consisted of a spiral colon (Fig. 12).



Fig. 11. Photograph of the coil of Small intestine from *Mazama americana* (1).

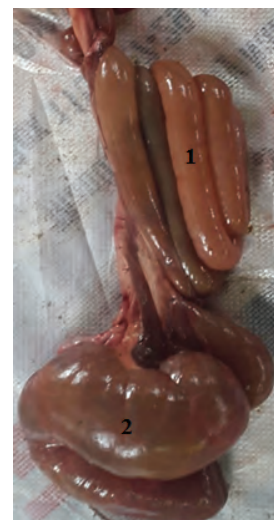

Fig. 12. Photograph showing the spiral colon (1) and the caecum (2) from *Mazama americana*.

The Combined Digestive System

The mouth of the red brocket deer has dental pads due to the absence of upper incisors by ruminant and has 32 teeth in total. There is a prominent incisive and transverse fold on the hard palate which runs in a caudal direction. The tongue is pointed and spatula shape with a prominent torus lingua (Table 2). The oesophagus is pink and long and connects the mouth to the reticulum (Figs. 1-5). The forestomach of the red brocket deer (the rumen, reticulum, omasum and abomasal mucosal surfaces) are similar to all domestic ruminants (Figs. 7-10). The abomasum (acid pepsin stomach) led into the small intestine. The small intestine measured 4.743 m in length, the duodenum, jejunum and ileum cannot be demarcated grossly (Fig. 11). The large intestine which measured 2.47 m in length (Table 2). The colon of the deer was tightly coiled and the caeca had no haustra (Fig. 12). The liver of the deer does not possess a gall bladder. The total length of the digestive tract was 8.73 m, which is approximately eight (8) times the length of the animal (Table 2). In situ, the intestines were covered by omentum. The diaphragm is the cranial portion of the abdominal cavity. It comes into contact with the reticulo-rumen. The abomasum can also be seen on the right side of the abdominal cavity (Figs. 13-14).

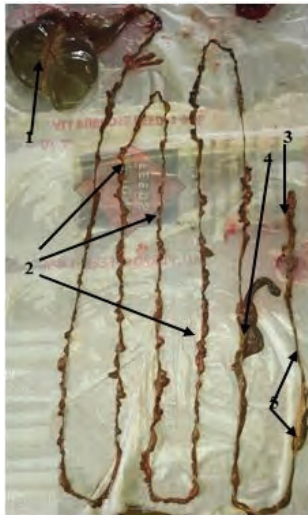


Fig. 13. Photograph of the digestive system. 1) Rumen; 2) Small intestine; 3) Rectum; 4) Caecum and 5) Colon.

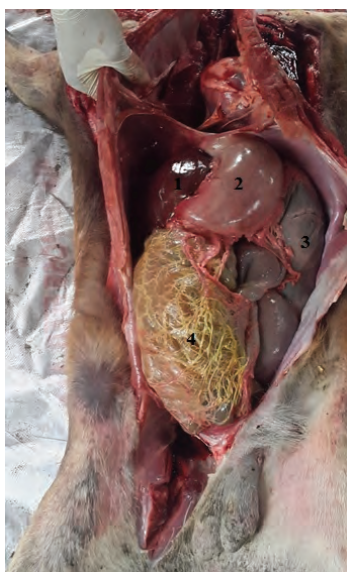


Fig. 14. Photograph showing organs in-situ 1) Liver; 2) Abomasum; 3) Rumen and 4) Omentum.

Table 3. Parameters of the gastrointestinal tract of the Red Brocket deer

Parameter	Result
Ratio of the length of the small intestine to that of the caecum/colon (gross intestines)	1.92
The length of the small intestine as % of total intestinal length	65.84%
The large intestine as a % of the total intestinal length	34.16%
Ratio of the length of the body to the length of the digestive tract	1:8.45

Discussion

This case study represented the gross and morphometric description of the gastrointestinal tract of the red brocket deer (*M. americana*). There has been very limited research done on the digestive systems and digestion in this and other *Mazama* spp. On the hard palate in *M. americana* there were transverse ridges, which were caudally directed and stopped at the level of the premolars, which was similar to what was observed by Hofmann (1988). Hofmann (1988) found that concentrate selectors had longer papillae arising from the caudal edge of the ridge and was used for consumption of fruits, forbes and foliage. Grass and roughage eaters have shorter papillae, which is necessary for consuming roughages. In the Samba deer (*Cervus unicolor*) the anterior two thirds of the hard palate had transverse processes and the posterior third was reported to be smooth. The tongue, cheeks and hard palate allow feed to move to the oesophagus (Sreeranjini *et al.*, 2010). The tongue of the red brocket deer was found to be spatula and pointed in shaped with a prominent torus lingua. These findings fall under the classification of a concentrate selector according to Hofmann (1988), where he stated that concentrate selectors have pointed tongues but grass and roughage eaters have large plump, piston like tongues.

The dentition in this specimen was similar to that described by Emmons and Feer (1990) for Cervidae. Alkins (1979) recorded similar findings for *M. americana trinitatis*. The stomach was composed of the four classical compartments of ruminants, which was consistent with the findings of Pérez and Vasquez (2012) for the brown brocket deer (*M. gouazoubira*). Some of the findings herein, such as the ruminal mucosa being evenly distributed with papillae, the lengths of the dorsal and ventral sacs of the rumen, the rumen's caudo-ventral blind sac being projected more caudally than the dorsal blind sac, the border of the intra-ruminal ostium being formed by the ruminal pillars, omasal folds and abomasal folds were also consistent with *Mazama* spp. (Pérez and Vasquez, 2012).

The length of the small intestine was 6.3625 m in the brown brocket deer (Pérez and Vasquez, 2012), which was similar to the finding here in of 4.743 m. However, they found that the length of the caecum and colon was 3.075 m, which was longer than the finding here in of 2.470 m (Table 3). The small intestine to gross intestine ratio was 2.0 (Pérez and Vasquez, 2012), while herein it was observed to be 1.92. Perez *et al.* (2008) found that the small intestine and caeco-colonic length was 495 cm and 237 cm for Pampa deer (*Ozotoceros bezoarcticus*). This gave a small intestine to caeco-colonic ratio of 2.08, which was similar to the brown brocket deer (Pérez *et al.*, 2008; Pérez and Vasquez, 2012). The brown brocket deer was classi-

fied as a concentrate selector as the small intestine to colonic ratio fell within the 1-2 range (Hofmann, 1989). Findings of this case study gave us a ratio of small intestines to gross intestines to be 1.92, which falls in the 1-2 range which is the range for concentrate selectors (Table 3). The anatomy of the tongue of the red brocket deer being pointed and spatula shaped suggests that it is a concentrate selector. Also the transverse ridges on the hard palate being caudally directed and longer also suggest that the red brocket deer is a concentrate selector. The red brocket deer seems to be a concentrate selector based on the anatomy of the tongue and hard palate.

Ruminants can be divided into concentrate selector, intermediate feeders and grass and roughage eaters (Hofmann, 1988). Concentrate selectors have small intestines of 65-73% and large intestine of 27-35% of the total intestinal length. Grass and roughage eaters have 80-82% small intestines with 18-20% large intestine (Hofmann, 1989; Van Soest, 1994). In the data that was collected in this case study the small intestines of the red brocket deer was 65.85% and a large intestine was 34.16% of the total intestinal length. This would group the red brocket deer as a concentrate selector (Table 3).

Grossly, the varying colours of the gastrointestinal tract were attributed to the start of decomposition (grey and brown). The characteristic honey-combed appearance of the mucosal surface of the reticulum and the characteristic folds of the omasum were observed and aided in identification. An additional interesting finding was that there was no gall bladder present, which was consistent with the findings in other Cervidae (Dyce et al., 1987).

Conclusion

At present there is a dearth of information regarding the gastrointestinal tract of the red brocket deer. The red brocket deer from our preliminary findings will have to be grouped with the ruminants which are concentrate selector due to the anatomy of the tongue, hard palatine and gastrointestinal findings. This animal did not possess a gall bladder which is true for other Cervidae species. The findings documented in this paper relates to only one specimen, thus it is recommended that a larger sample size be used to get a better idea of the gross anatomy and the measurements of the different parts of the gastrointestinal tract of the red brocket deer at different physiological states.

Conflict of interest

There is no conflict of interest amongst authors

Acknowledgement

We would like to sincerely thank Mr. Murchison Pierre, who notified us about the death of the deer, as this case study would not have been possible without his help. Special thanks Emeritus Professor Holman Eugene Williams for his vital comment on the draft manuscript.

References

- Alkins, M.E., 1979. The Mammals of Trinidad. No. 2. Department of Zoology, University of the West Indies, St. Augustine, Trinidad.
- Animalia, 2017 Red Brocket – *Mazama americana*. Accessed November 2nd, 2017. <http://animalia.bio/red-brocket>.
- Bodmer, R.E., 1989. Frugivory in Amazonian Artiodactyla: Evidence for the Evolution of the Ruminant Stomach. *Journal of Zoology* 219 (3), 457-467.
- Bodmer, R.E., 1991a. Influence of Digestive Morphology on Resource Partitioning in Amazonian Ungulates. *Oecologia* 85 (3), 361-365.
- Bodmer, R.E., 1991b. Strategies of Seed Dispersal and Seed Predation in Amazonian Ungulates. *Biotropica* 23 (3), 255-261.
- Church, D.C., 1977. *Livestock Feeds and Feeding* 3rd Edition. Prentice Hall, Eaglewood Cliffs, New Jersey.
- Church, D.C., 1976. *Digestive Physiology of Nutrition of Ruminants*. Volume 1, 2nd Edition. D.C. Church. Oxford Press Inc.
- de Lázari, P.R., Manoel, dos Santos-Filho, Gustavo R.C., Maurício E.G., 2013. Flood-Mediated Use of Habitat by Large and Midsized Mammals in the Brazilian Pantanal. *Biota Neotropica* 13 (2), 70-75.
- Dyce, K.M., Sack, W.O., Wengsing, G.J.G., 1987. *Textbook of Veterinary Anatomy*. W.B Saunders Company. Harcourt Brace Jovanovich Inc.
- Eisenberg, J. F., Redford, H.R., 1999. *Mammals of the Neo-tropics: The Central Neo-tropics: Ecuador, Peru, Bolivia, Brazil*. Volume 3. Chicago: The University of Chicago Press.
- Emmons, L.H., Feer F., 1990. *Neotropical Rainforest Mammals. A Field Guide*. Chicago: University of Chicago Press.
- Garcia, G.W., Baptiste, Q.S., Adogwa, A.O., Kakuni, M., Arishima, K., Makita, T., 2000. The Digestive System of the Agouti (*Dasyprocta leporina*) – Gross Anatomy and Histology. *Japanese Journal of Zoo and Wildlife Medicine* 5(1), 55-66.
- Hofmann, R.R., 1989. Evolutionary Steps of Ecophysiological Adaptation and Diversification of Ruminants: A Comparative view of Their Digestive System. *Oecologia* 78, 443-457.
- Hofmann, R.R., 1988. Anatomy of the Gastrointestinal tract. In: *The Ruminant animal: Digestive Physiology and Nutrition*. D.C. Church (Editor). Prentice Hall Cliffs, Eaglewood, New Jersey.
- Hurtado-Gonzales, J.L., Bodmer, R.E., 2004. Assessing the Sustainability of Brocket Deer Hunting in the Tamshiyacu-Tahuayo Communal Reserve, North eastern Peru. *Biological Conservation* 116 (1), 1-7.
- Mollineau, W., Adogwa, A., Jasper, N., Young, K. and Garcia, G., 2006. The Gross anatomy of the male reproductive system of a neotropical rodent: the Agouti (*Dasyprocta leporina*). *Anatomy, Histology and Embryology* 35:47-52
- Perez, W. Clauss, M., Ungerfeld, P., 2008. Observation on the macroscopic anatomy of the intestinal tract and its mesenteric folds in the pampas deer (*Ozotoceros bezoarticus*, Linnaeus 1758). *Anatomia, Histologia and Embryologia* 37(4), 317-321.
- Pérez, W., Vazquez, N., 2012. Gross Anatomy of the Gastrointestinal Tract in the Brown Brocket Deer (*Mazama gouazoubira*). *Journal of Morphological Sciences* 29 (3), 148-150.
- Shiple, L.A., 1999. Grazers and Browsers: How Digestive Morphology affects diet selection. Presented in "Grazing Behaviour of Livestock and Wildlife". Idaho Forest, Wildlife and Range Exp. Sta. Bull. #70, University of Idaho, Moscow.
- Singh, D.M., Adogwa, A., Mollineau, W., Garcia G., 2014. Gross and microscopic anatomy of the reproductive tract of the female agouti (*Dasyprocta leporina*): A neo-tropical rodent with potential for food production. *Tropical Agriculture (Trinidad)* 91 (1), 38-46.
- Sreeranjini, A.R., Ravani, C.V., Ashok, N., 2010. Gross anatomical studies on the hard palate, tongue and buccal floor in Samba deer (*Cervus unicolor*). *Tamilnadu Journal of Veterinary and Animal Science* 6(4), 151-156.
- Tobler, M.W., Carrillo-Percegué, S.E., Powell, G., 2009. Habitat Use, Activity Patterns and Use of Mineral Licks by Five Species of Ungulate in South-Eastern Peru. *Journal of Tropical Ecology* 25 (3), 261-270.
- Ultimate ungulate., 2017. *Mazama americana – Red Brocket Deer*. Accessed November 2nd, 2017. http://www.ultimateungulate.com/Artiodactyla/Mazama_americana.html.
- Van Soest, P.J., 1994. *Nutritional ecology of the Ruminant*. 2nd Edition. Cornell University Press, Ithaca. New York.